



Review

Biomechanical impact of vertebroplasty

Postoperative biomechanics of vertebroplasty

Gamal Baroud ^{a,*}, Marc Bohner ^b^a *Biomechanics Laboratory, Mechanical Engineering Department, Sherbrooke University, J1K 2R1 Sherbrooke, Quebec, Canada*^b *Dr hc Robert Mathys Foundation, Bettlach, Switzerland*

Received 19 May 2004; accepted 26 February 2005

Abstract

Objectives. – To examine the biomechanisms underlying adjacent fractures following vertebroplasty, an emerging procedure to stabilize fractured vertebrae. In this procedure, bone cement is injected percutaneously into the vertebral cancellous bone. Once hardened, the cement offers mechanical reinforcement to the weakened vertebra. Recent clinical and biomechanical reports suggest that this procedure may cause new fractures adjacent to the one augmented. The cause and extend is unclear yet. The focus here is on the biomechanical hypothesis resulting from the rigid cement augmentation.

Methods. – A combination of experimental and numerical studies, in addition to a review of recent clinical reports.

Results. – The broader finding suggests that vertebroplasty changes the mechanical loading in adjacent vertebrae. Specifically, an increase in adjacent loading in the range of 17% has been found. The mechanism underlying this increase seemed to stem from the excessive cement rigidity that reduced the endplate bulge of the augmented vertebra, thereby reducing the local spinal joint flexibility. The reduction in joint flexibility seeks to reverse itself by creating an increase in the inter-vertebral disc pressure. The increased disc pressure seeks to relieve itself by increasing the load on the adjacent vertebra. The increased load on the adjacent vertebra relates directly to an increased risk of fracture.

Conclusions. – Although an increasing amount of evidence exists to support this theory of the origin of adjacent fractures, one must be cautious. Vertebroplasty is a relatively new procedure and further observations and, ultimately, prospective clinical studies are required to conclusively determine the cause and extend of adjacent fractures.

© 2005 Elsevier SAS. All rights reserved.

Keywords: Vertebroplasty; Polymethylmethacrylate; Adjacent fractures; Biomechanics**1. Introduction**

Vertebroplasty consists in injecting polymethylmethacrylate (PMMA) into the cavities of a diseased vertebra with the dual goal of increasing mechanical resistance and alleviating pain [1–7]. PMMA has been widely used in orthopedic surgery for several decades, most notably to secure joint prostheses to host bone. In 1987, Galibert et al. (1987) suggested percutaneous PMMA injection to prevent mechanical instability of vertebrae harboring aggressive hemangiomas. Their article marked the birth of vertebroplasty in France. In 1990, Galibert and Deramond (1990) used vertebroplasty to

strengthen osteoporotic vertebrae [8]. Other groups in France soon adopted vertebroplasty [2,9–17], and about a decade later groups in the US followed suit [18–21]. Now, vertebroplasty is used around the world to treat aggressive vertebral hemangiomas, bone metastases, and spinal osteoporosis.

Patients report pain alleviation almost immediately after the procedure in 80–97% of cases, a result that has boosted the popularity of vertebroplasty [3,5,18,22–27]. Vertebroplasty not only improves quality of life but is also inexpensive, with a cost in physician fees and supplies of \$150–300 per vertebra [28]. Among adverse events, the most serious is cement leakage outside the vertebra [10,13,22,29–34]. In a very small minority of cases, cement leakage causes devastating complications, such as neurological damage or embolism. In addition, clinical and biomechanical evidence sug-

* Corresponding author. Tel.: +1 819 821 8000x2119; fax: +1 819 821 7163.

E-mail address: Gamal.Baroud@usherbrooke.ca (G. Baroud).

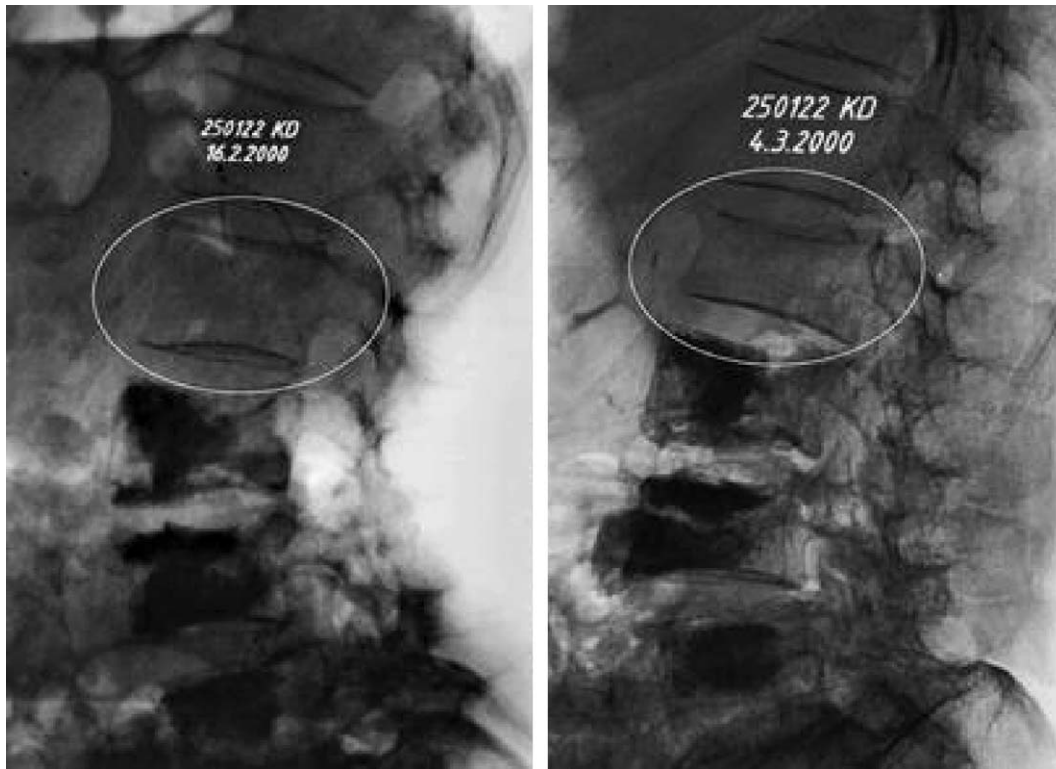


Fig. 1. The radiograph on the left was taken immediately after vertebroplasty and the radiograph on the right 2 weeks later. This second radiograph shows a compression vertebral fracture adjacent to the cemented vertebra from [37], with permission.

gests that strengthening a vertebra by vertebroplasty [35–41] may increase the fracture risk in vertebrae adjacent (Fig. 1) [42–45]. Although the reasons remain poorly understood [35–37,42–45], they may involve the considerable rigidity of acrylic cement used for vertebroplasty.

Heat-induced damage is another source of adverse effects related to acrylic cement vertebroplasty. The exothermal reaction produced when the cement solidifies can cause necrosis of bone and neighboring tissues [46–48]. Finally, toxicity due to passage of the nonreactive liquid monomer into the blood and bone tissue has been reported [49].

Although each of these risks has a crucial impact on the safety of vertebroplasty, here we will discuss only fractures in adjacent vertebrae. Our objective is to review biomechanical data on fractures in adjacent vertebrae in order to shed light on the underlying mechanisms. We will explore the hypothesis that adjacent fractures are related to changes in mechanical loads induced by the cement. The outline of this article is given below.

- First, we will report original experimental data on the mechanical properties of five cements recently introduced for vertebroplasty. We will compare these properties to those of untreated osteoporotic bone and of osteoporotic bone filled with acrylic cement.
- Second, we will describe two mechanical models of the spine used to investigate vertebroplasty-related changes in biomechanical loads through the adjacent vertebrae, review the results of these studies, and look at their practical implications. We will present an experimental model for adja-

cent fractures; again, the results and their implications will be discussed.

- Third, the results from the three biomechanical models described above will be compared, contrasted, and discussed with the goal of understanding adjacent fractures, thereby drawing conclusions of practical importance to clinicians.

2. Mechanical properties of five cements used for vertebroplasty

We will look at the mechanical properties of five cements used for vertebroplasty, as well as of untreated osteoporotic bone and osteoporotic bone filled with cement. The elastic modulus and ultimate strength are the mechanical parameters of greatest interest. The elastic modulus represents the stiffness of the material. Similar to pressure, the elastic modulus is a force per unit surface area, and is therefore, given in Pascals (1 bar = 10^5 Pa) or, more often, Megapascals (1 MPa, 1 million Pascals). Cortical bone has a higher elastic modulus (18,000 MPa) than that of cancellous bone (150 MPa): cortical bone is nearly 100 times stiffer. Ultimate strength is the amount of pressure that can be applied to a material without causing damage. Cortical bone has an ultimate strength 25 times greater than that of cancellous bone (100 vs. 4 MPa). Both the elastic modulus and ultimate strength of bone are heavily influenced by age, severity of osteoporosis, skeletal site, and other factors. The presence of cement within cancel-

lous bone cavities would be expected to modify the elastic modulus and ultimate strength.

2.1. Characterizing the elastic modulus and ultimate strength

We studied five cements (Biopex, Norian SRS, Vertebroplastic, Cranioplastic, and Simplex), as well as untreated osteoporotic bone and osteoporotic bone whose cavities were completely filled with Simplex cement. Biopex and Norian SRS are calcium phosphate-based ionic cements that are being introduced for vertebroplasty. Both cements release heat slowly, which minimizes the risk of necrosis; however, their radiodensity is not well suited to vertebroplasty. The same is true of Simplex and Cranioplastic; these two cements and Vertebroplastic are polymers that rapidly release large amounts of heat. Simplex was developed for securing hip prostheses, Cranioplastic for filling skull defects, and Vertebroplastic for vertebroplasty.

Sophisticated methods for investigating the mechanical properties of cements have been described [50]. In 2000, Pitet and Lemaître reported the use of Mohr's circles to determine mechanical compressive, tensile, and shear strength. This method is of great interest in the study of phosphate calcium cements, given their sensitivity to tensile and shear loads. It was not used in the present study because our main goal was to investigate the effects of cement-induced strengthening of one vertebra on the propensity of adjacent vertebrae to fracture. This propensity depends only on the resistance to compression of the cement in the treated vertebra. Therefore, in addition to stiffness, we measured resistance to compression of the studied cements. Resistance to compression is widely described as the main parameter of interest when investigating cements injected into confined spaces (e.g. a vertebra) [35–41]. (In a nonconfined space, resistance to shear forces is far greater.) Finally, resistance to fatigue (e.g. during compression) is relevant to vertebroplasty but will be investigated in a subsequent study.

Cement samples were prepared in compliance with ISO5833. In particular, the powder-to-liquid ratio was kept constant. Mixtures were prepared as recommended by the manufacturers (e.g. for Norian SRS, the mixing machine supplied with the cement was used). Each cement mixture was drawn up into a syringe (confined space) and allowed to set at room temperature (23 °C). Completion of the setting reaction, as assessed by X-ray diffraction, required 24 hours for the polymers and 1 week for the calcium phosphate cements (Norian SRS et Biopex). To ensure proper setting of the cement within bone, we left bone–cement specimens undisturbed for 2–3 days. The bones were then cut to obtain 10 cylinders identical in diameter and height (8.4 ± 1.6 mm; slight height variations were due to the presence of air bubbles). In a clinical setting, cement is usually injected into vertebral cancellous bone. Therefore, we used cancellous bone for our experiments. We collected 20 specimens of cancellous bone from two human spines with osteoporosis (age,

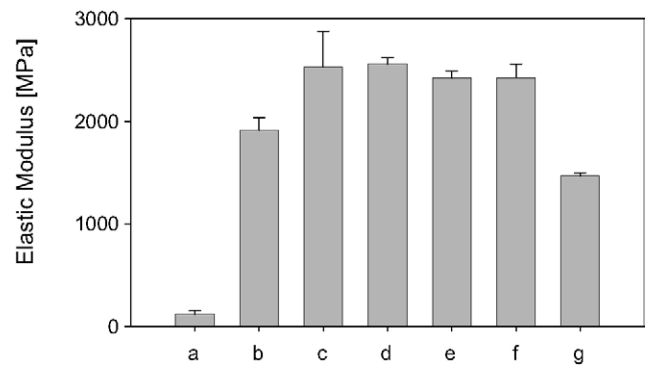


Fig. 2. Elastic modulus (\pm empirical standard deviation (S.D.)) in (a) untreated osteoporotic cancellous bone, (b) Biopex cement, (c) Norian SRS cement, (d) Vertebroplastic cement, (e) Cranioplastic cement, (f) Simplex cement, and (g) osteoporotic cancellous bone completely filled with Simplex cement.

69.7 ± 6.6 years, bone mineral density, 0.59 ± 0.14 g cm⁻²) and separated them into two groups at random. One group of 10 specimens was left untreated, whereas the second group was injected with Simplex cement in order to achieve complete filling of bone cavities.

2.2. Results

All five cements had higher elastic modulus values (> 2000 MPa) than that of osteoporotic cancellous bone (≈ 80 MPa). The cements were about 20 times stiffer than the osteoporotic cancellous bone (Fig. 2). The ultimate strength of the cements was 36 times greater, on average, than that of bone (Fig. 3). Thus, injecting cement into bone causes major changes in mechanical properties. On average, the bone–cement specimens showed a 12-fold increase in stiffness (Fig. 2) and a 36-fold increase in ultimate strength (Fig. 3), as compared to osteoporotic cancellous bone.

2.3. Implications of the results

Increasing the ultimate strength of the treated vertebra is among the goals of vertebroplasty. Vertebroplasty not only improves the mechanical stability of the fractured vertebra,

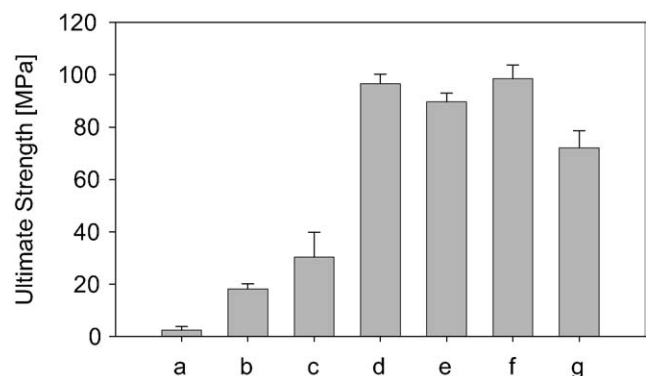
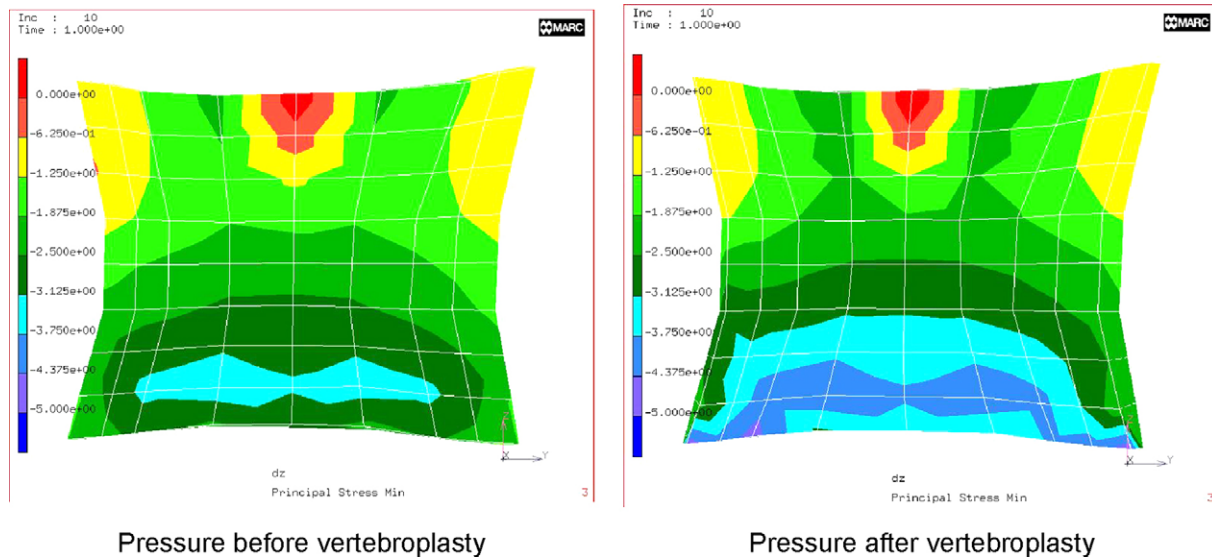


Fig. 3. Ultimate strength (\pm empirical S.D.) in (a) untreated osteoporotic cancellous bone, (b) Biopex cement, (c) Norian SRS cement, (d) Vertebroplastic cement, (e) Cranioplastic cement, (f) Simplex cement, and (g) osteoporotic cancellous bone completely filled with Simplex cement.



Pressure before vertebroplasty

Pressure after vertebroplasty

Fig. 4. Pressure in the sagittal plane in L4, before and after, L3 vertebroplasty. Note the higher pressure and greater surface area of pressure distribution after vertebroplasty. From [37], with permission.

but also prevents further vertebral collapse and loss of vertebral height. Ultimate strength shows an impressive 36-fold increase. To this date, no adverse effects have been ascribed to this strength increase.

The at least 10-fold increase in elastic modulus is also clinically desirable, as it decreases or prevents micromotion within the abnormal vertebra. Micromotion usually causes pain; the palliative pain-relieving effect of vertebroplasty has been related to improved mechanical stability and decreased micromotion within the fractured vertebra [42,46–48]. However, the increased stiffness of the treated vertebra may exert undesirable effects on adjacent tissues. Increases as large as those seen in our study (about 12-fold) usually result in a redistribution of mechanical loads within the overall structure of the spine [37,40,42,51,52]. This deserves further discussion.

3. Changes in mechanical loads through the adjacent vertebrae

Fractures in vertebrae adjacent to vertebroplasty sites are being increasingly reported [5,19,43–45,51–54]. Unfortunately, there still little information available on the biomechanical factors involved. We reviewed the literature for biomechanical studies of adjacent vertebrae after vertebroplasty.

Adjacent fractures are commonly ascribed to a pressure increase induced by vertebroplasty [35–37,40,42,52]. As mentioned above, the stiffness of the cancellous bone in the treated vertebra increases 12-fold. This major change in vertebral body stiffness may redistribute loads through the treated vertebra and, therefore, through the adjacent tissues. Data from other areas of orthopedic surgery support this possibility [55]. Changes in mechanical loads transferred through total hip prostheses with stiff fixations can result in damage to proximal femoral tissue, cancellous bone remodeling and potential implant failure due to poor anchoring. To investigate the

hypothesis that a change in pressure may cause adjacent vertebral fractures after vertebroplasty, two independent groups developed similar computer models [36,37,52]. In both models, the measurements involved the smallest possible spinal unit, namely, two lumbar vertebrae and the intervertebral disk. Three-dimensional units were constructed using computed tomography scanning and the finite-element method. Finite-element models are widely used by engineers to investigate pressures within complex mechanical structures. The position of the intervertebral disk and nucleus pulposus was selected based on measurements of human specimens [36,37,52].

3.1. Results

Both studies found significant pressure elevations around the cemented vertebrae [36,37,52]. Pressures in the adjacent vertebrae increased by about 13–18%. In addition, an increase was found in the surface area receiving pressure loads from the treated vertebra (Fig. 4). The cement seems to act as an upright pillar preventing the endplates of the treated vertebra from sinking into the vertebral body [36,37,52]. The result is a major pressure increase in the adjacent nucleus pulposus, and therefore, in the adjacent vertebra. These data establish that the cement causes major changes in mechanical loads and that these changes extend beyond the treated vertebra into the adjacent vertebrae.

3.2. Experimental implications

The up to 18% pressure increase in adjacent vertebrae suggested by the computer-model studies may have a major effect on bone previously weakened by osteoporosis or an aggressive hemangioma. Therefore, experiments should be able to detect these effects. In 2002, Berlemann et al. described the first experimental model for investigating changes in adja-

cent vertebrae [42]. Twenty segments, each composed of two cadaver vertebrae, were prepared. Ten segments were treated by injection of cement into one of the vertebrae and 10 segments were left untreated (control group). Ultimate strength was then measured by applying standardized compression using a servohydraulic testing machine (Mini Bionix 856, MTS, Eden Prairie, MN). Mean ultimate strength was 17% lower in the treated group than in the control group [42]. In the treated group, all fractures occurred in the adjacent vertebra, not the injected vertebra. These data support the pressure elevation hypothesis and show that cement injection, while increasing local strength, may weaken the adjacent vertebrae. A similar model was described in 2003 by Ananthakrishnan et al. [56], who inserted a pressure sensor into the intervertebral disk next to the cemented vertebra. Results showed a significant increase in disk hydrostatic pressure, although the exact value is not specified in the report. These data, together with the consistency between data from experimental and computer-generated models, support pressure elevation in the adjacent vertebrae as a cause for adjacent fractures after vertebroplasty.

4. Discussion

Cements are far stiffer than cancellous bone. Injecting cement into vertebral cavities considerably increases the stiffness and ultimate strength of the vertebra, as established by an abundance of biomechanical data. These changes produce a large pressure increase in the adjacent vertebrae.

Few clinical cases of adjacent vertebral fractures were reported initially. In 1998, Deramond mentioned the risk of new fractures. Fractures were also described in small subgroups of patients with osteoporosis [5,11,19,41–44,53,57,58]. More recently, two clinical studies found significantly increased risks of vertebral fractures in the vicinity of cemented vertebrae. In 2000, Grados et al. reported follow-up data from 25 patients who underwent percutaneous vertebroplasty and had a mean follow-up of 48 months [43]. The odds ratio for vertebral fractures near the cemented vertebra was 2.27 with a 95% confidence interval of 1.1–4.56; the odds ratio of vertebral fracture near an uncemented fractured vertebra was not significantly increased (1.44; 95% confidence interval, 0.82–2.55). Three years later, Uppin et al. reported data from 177 patients treated with percutaneous vertebroplasty for vertebral osteoporosis [44]. During the 2 year follow-up, 22 patients experienced 36 new fractures, of which 24 were vertebrae adjacent to the vertebroplasty site; the risk increase for fractures in adjacent vertebrae was significant. In addition, 24 of the 36 fractures occurred within 30 days after percutaneous vertebroplasty.

Despite the clinical evidence supporting an increased risk of fracture in vertebrae adjacent to vertebroplasty sites and the biomechanical studies suggesting a plausible mechanism to these fractures, there is still no proof that vertebroplasty causes adjacent fractures. Prospective clinical studies are needed to better understand the risk of adjacent fractures.

Other hypotheses have been put forward to explain adjacent fractures. Uppins et al. [44], noted that the improvements seen rapidly after vertebroplasty allowed a higher level of physical activity. Greater physical activity is associated with increased pressure loads through vertebrae, and therefore, in a higher risk of vertebral fractures. Heini et al. (2004) also suggested this mechanism.

Furthermore, adjacent fractures may merely reflect the natural progression of osteoporosis. Indeed, the risk for experiencing a second fracture is increased fourfold as compared to the risk for the first fracture, in the absence of vertebroplasty [59–61]. These hypotheses are not mutually exclusive. Thus, increased physical activity and/or the stiffness of the cement may combine with osteoporosis progression to increase the risk of adjacent fractures [37,44,59–61].

If stiffness of the cement is considered a major factor in the risk of adjacent fractures, then the current practice of filling the vertebra as much as possible deserves reappraisal. Complete filling may not be indispensable to achieve effective vertebroplasty. Completely cemented cancellous bone is 36 times stronger than uncemented bone, as mentioned above. Belkoff et al. [39], recommended restoring stiffness and ultimate strength to normal values. Several studies found a positive linear correlation between the degree of filling and restoration of both ultimate strength and stiffness. Furthermore, Belkoff et al. [39], reported that 2 ml of cement was sufficient to normalize the ultimate strength of osteoporotic vertebra from cadavers. Clinical studies are needed to evaluate the effects of cement volume in vivo. A better solution would consist in developing cements characterized by lower stiffness, in order to minimize the pressure increase in adjacent vertebrae.

5. Conclusion

Clinical studies have found a significant increase in the risk of vertebral fractures near cemented vertebrae. Whether the increased fracture risk is related to biomechanical changes and/or to greater physical activity as a result of pain relief remains unclear. Should the biomechanical hypothesis be confirmed, reducing the volume of cement or developing cements with lower stiffness values would become key goals in the improvement of vertebroplasty.

Acknowledgments

Supported by the Canadian Institute of Health Research (CIHR) Grant Number MOP 57835.

References

- [1] Galibert P, Deramond H, Rosat P, Le Gars D. Note préliminaire sur le traitement des angiomes vertébraux par vertébroplastie acrylique percutanée. *Neurochirurgie* 1987;33:166–8.

- [2] Cortet B, Cotten A, Deprez X, Deramond H, Lejeune JP, Leclerc X, et al. Interet de la vertebroplastie couplée a une décompression chirurgicale dans le traitement des angiomes vertébraux agressifs. À propos de trois cas. *Rev Rhum Ed Fr* 1994;61:16–22.
- [3] Deramond H, Depriester C, Toussaint P, Galibert P. Percutaneous vertebroplasty. *Semin Musculoskelet Radiol* 1997;1:285–96.
- [4] Fourny DR, Schomer DF, Nader R, Chlan-Fourny J, Suki D, Ahrar K, et al. Percutaneous vertebroplasty and kyphoplasty for painful vertebral body fractures in cancer patients. *J Neurosurg* 2003;98S:21–30.
- [5] Heini PF, Walchli B, Berlemann U. Percutaneous transpedicular vertebroplasty with PMMA: operative technique and early results. A prospective study for the treatment of osteoporotic compression fractures. *Eur Spine J* 2000;9:445–50.
- [6] Phillips FM, Pfeifer BA, Lieberman IH, Kerr 3rd EJ, Choi IS, Pazzianos AG. Minimally invasive treatments of osteoporotic vertebral compression fractures: vertebroplasty and kyphoplasty. *Instr Course Lect* 2003;52:559–67.
- [7] Gangi A, Guth S, Imbert JP, Marin H, Dietemann JL. Percutaneous vertebroplasty: indications, technique, and results. *Radiographics* 2003;23:e10.
- [8] Galibert P, Deramond H. Percutaneous acrylic vertebroplasty as a treatment of vertebral angioma as well as painful and debilitating diseases. *Chirurgie* 1990;116:326–34.
- [9] Cotten A, Deramond H, Cortet B, Lejeune JP, Leclerc X, Chastanet P, et al. Preoperative percutaneous injection of methyl methacrylate and N-butyl cyanoacrylate in vertebral hemangiomas. *AJNR Am J Neuroradiol* 1996;17:137–42.
- [10] Deramond H, Galibert P, Depriester-Debussche C. Injections intraosseuses percutanées dans le traitement palliatif des métastases osseuses. *Bull Cancer* 1993;80S:36–40.
- [11] Chiras J, Depriester C, Weill A, Sola-Martinez MT, Deramond H. Percutaneous vertebral surgery. Techniques and indications. *J Neuroradiol* 1997;24:45–59.
- [12] Rapado A. General management of vertebral fractures. *Bone* 1996;18S:191S–196S.
- [13] Weill A, Chiras J, Simon JM, Rose M, Sola-Martinez T, Enkaoua E. Spinal metastases: indications for and results of percutaneous injection of acrylic surgical cement. *Radiology* 1996;199:241–7.
- [14] Feydy A, Cognard C, Miaux Y, Sola Martinez MT, Weill A, Rose M, et al. Acrylic vertebroplasty in symptomatic cervical vertebral haemangiomas: report of two cases. *Neuroradiology* 1996;38:389–91.
- [15] Dousset V, Mousselet H, de Monck d'User L, Bouvet R, Bernard P, Vital JM, et al. Asymptomatic cervical haemangioma treated by percutaneous vertebroplasty. *Neuroradiology* 1996;38:392–4.
- [16] Cotten A, Dewatre F, Cortet B, Assaker R, Leblond D, Duquesnoy B, et al. Percutaneous vertebroplasty for osteolytic metastases and myeloma: effects of the percentage of lesion filling and the leakage of methyl methacrylate at clinical follow-up. *Radiology* 1996;200:525–30.
- [17] Ide C, Gangi A, Rimmelin A, Beaujeux R, Maitrot D. Buchheit Fet al. Vertebral haemangiomas with spinal cord compression: the place of preoperative percutaneous vertebroplasty with methyl methacrylate. *Neuroradiology* 1996;38:585–9.
- [18] Jensen ME, Dion JE. Vertebroplasty relieves osteoporosis pain. *Diagn Imaging (San Franc)* 1997;19(68):71–2.
- [19] Jensen ME, Evans AJ, Mathis JM, Kallmes DF, Cloft HJ, Dion JE. Percutaneous polymethylmethacrylate vertebroplasty in the treatment of osteoporotic vertebral body compression fractures: technical aspects. *AJNR Am J Neuroradiol* 1997;18:1897–904.
- [20] Bostrom MP, Lane JM. Future directions. Augmentation of osteoporotic vertebral bodies. *Spine* 1997;22:38S–42S.
- [21] Mathis JM, Petri M, Naff N. Percutaneous vertebroplasty treatment of steroid-induced osteoporotic compression fractures. *Arthritis Rheum* 1998;41:171–5.
- [22] Cotten A, Boutry N, Cortet B, Assaker R, Demondion X, Leblond D, et al. Percutaneous vertebroplasty: state of the art. *Radiographics* 1998;18:311–20 (discussion 320–3).
- [23] Deramond H, Mathis JM. Vertebroplasty in osteoporosis. *Semin Musculoskelet Radiol* 2002;6:263–8.
- [24] Kallmes DF, Jensen ME. Percutaneous vertebroplasty. *Radiology* 2003;229:27–36.
- [25] Lieberman I, Reinhardt MK. Vertebroplasty and kyphoplasty for osteolytic vertebral collapse. *Clin Orthop* 2003;415:S176–86.
- [26] Mathis JM. Percutaneous vertebroplasty: complication avoidance and technique optimization. *AJNR Am J Neuroradiol* 2003;24:1697–706.
- [27] Mathis JM, Barr JD, Belkoff SM, Barr MS, Jensen ME, Deramond H. Percutaneous vertebroplasty: a developing standard of care for vertebral compression fractures. *AJNR Am J Neuroradiol* 2001;22:373–81.
- [28] Fisher A. Percutaneous vertebroplasty: A bone cement procedure for spinal pain relief. *Issues in emerging health technologies* 2002;31:1–4.
- [29] Phillips FM, Todd Wetzel F, Lieberman I, Campbell-Hupp M. An in vivo comparison of the potential for extravertebral cement leak after vertebroplasty and kyphoplasty. *Spine* 2002;27:2173–8.
- [30] Breusch S, Heisel C, Mueller J, Borchers T, Mau H. Influence of cement viscosity on cement interdigitation and venous fat content under in vivo conditions. *Acta Orthop Scand* 2002;73:409–15.
- [31] Chen HL, Wong CS, Ho ST, Chang FL, Hsu CH, Wu CT. A lethal pulmonary embolism during percutaneous vertebroplasty. *Anesth Analg* 2002;95:1060–2 (table of contents).
- [32] Do HM. Intraosseous venography during percutaneous vertebroplasty: is it needed? *AJNR Am J Neuroradiol* 2002;23:508–9.
- [33] Francois K, Taeymans Y, Poffyn B, Van Nooten G. Successful management of a large pulmonary cement embolus after percutaneous vertebroplasty: a case report. *Spine* 2003;28:E424–E425.
- [34] Bohner M, Gasser B, Baroud G, Heini P. Theoretical and experimental model to describe the injection of a polymethylmethacrylate cement into a porous structure. *Biomaterials* 2003;24:2721–30.
- [35] Baroud G. Material changes in osteoporotic human cancellous bone following infiltration with acrylic bone cement for a vertebral cement augmentation. *Comput Methods Biomech Biomed Engin* 2003;6:133–9.
- [36] Baroud G, Heini P, Nemes J, Bohner M, Ferguson S, Steffen T. Biomechanical explanation of adjacent fractures following vertebroplasty. *Radiology* 2003;229:606–7.
- [37] Baroud G, Nemes J, Heini P, Steffen T. Load shift of the intervertebral disc after a vertebroplasty: a finite-element study. *Eur Spine J* 2003;12:421–6.
- [38] Belkoff SM, Mathis JM, Jasper LE. Ex vivo biomechanical comparison of hydroxyapatite and polymethylmethacrylate cements for use with vertebroplasty. *AJNR Am J Neuroradiol* 2002;23:1647–51.
- [39] Belkoff SM, Mathis JM, Jasper LE, Deramond H. The biomechanics of vertebroplasty. The effect of cement volume on mechanical behavior. *Spine* 2001;26:1537–41.
- [40] Liebschner MA, Rosenberg WS, Keaveny TM. Effects of bone cement volume and distribution on vertebral stiffness after vertebroplasty. *Spine* 2001;26:1547–54.
- [41] Heini PF, Berlemann U, Kaufmann M, Lippuner K, Fankhauser C, van Landuyt P. Augmentation of mechanical properties in osteoporotic vertebral bones — a biomechanical investigation of vertebroplasty efficacy with different bone cements. *Eur Spine J* 2001;10:164–71.
- [42] Berlemann U, Ferguson SJ, Nolte LP, Heini PF. Adjacent vertebral failure after vertebroplasty. A biomechanical investigation. *J Bone Joint Surg Br* 2002;84:748–52.
- [43] Grados F, Depriester C, Cayrolle G, Hardy N, Deramond H, Fardellone P. Long-term observations of vertebral osteoporotic fractures treated by percutaneous vertebroplasty. *Rheumatology (Oxford)* 2000;39:1410–4.

- [44] Uppin AA, Hirsch JA, Centenera LV, Pfeifer BA, Pazianos AG, Choi IS. Occurrence of new vertebral body fracture after percutaneous vertebroplasty in patients with osteoporosis. *Radiology* 2003;226:119–24.
- [45] Hardouin P, Grados F, Cotten A, Cortet B. Should percutaneous vertebroplasty be used to treat osteoporotic fractures? An update. *Joint Bone Spine* 2001;68:216–21.
- [46] Belkoff SM, Molloy S. Temperature measurement during polymerization of polymethylmethacrylate cement used for vertebroplasty. *Spine* 2003;28:1555–9.
- [47] Deramond H, Wright NT, Belkoff SM. Temperature elevation caused by bone cement polymerization during vertebroplasty. *Bone* 1999;25:17S–21S.
- [48] Baroud G, Samara M, Steffen T. Influence of mixing method on the cement temperature-mixing time history and doughing time of three acrylic cements for vertebroplasty. *J Biomed Mater Res* 2004;68B:112–6.
- [49] San Millan Ruiz D, Burkhardt K, Jean B, Muster M, Martin JB, Bouvier J, et al. Pathology findings with acrylic implants. *Bone* 1999;25:85S–90S.
- [50] Pittet C, Lemaître J. Mechanical characterization of brushite cements: a Mohr circles' approach. *J Biomed Mater Res* 2000;53:769–80.
- [51] Baroud G, Nemes J, Ferguson SJ, Steffen T. Material changes in osteoporotic human cancellous bone following infiltration with acrylic bone cement for a vertebral cement augmentation. *Comput Methods Biomech Biomed Engin* 2003;6:133–9.
- [52] Polikeit A, Nolte LP, Ferguson SJ. The effect of cement augmentation on the load transfer in an osteoporotic functional spinal unit: finite-element analysis. *Spine* 2003;28:991–6.
- [53] Zoarski GH, Snow P, Olan WJ, Stallmeyer MJ, Dick BW, Hebel JR, et al. Percutaneous vertebroplasty for osteoporotic compression fractures: quantitative prospective evaluation of long-term outcomes. *J Vasc Interv Radiol* 2002;13:139–48.
- [54] Deramond H, Depriester C, Galibert P, Le Gars D. Percutaneous vertebroplasty with polymethylmethacrylate. Technique, indications, and results. *Radiol Clin North Am* 1998;36:533–46.
- [55] Huiskes R, Weinaus H, van Rietbergen B. The relationship between stress shielding and bone resorption around total hip stems and the effects of flexible materials. *Clin Orthop* 1992;274:124–34.
- [56] Ananthakrishnan D, Lotz JC, Berven S, Puttlitz C. Changes in spinal loading due to vertebral augmentation: vertebroplasty versus kyphoplasty. In: Annual Meeting of the American Academy of Orthopaedic Surgeons. 2003. p. 472 (New Orleans).
- [57] Cortet B, Cotten A, Boutry N, Flipo RM, Duquesnoy B, Chastanet P, et al. Percutaneous vertebroplasty in the treatment of osteoporotic vertebral compression fractures: an open prospective study. *J Rheumatol* 1999;26:2222–8.
- [58] Barr JD, Barr MS, Lemley TJ, McCann RM. Percutaneous vertebroplasty for pain relief and spinal stabilization. *Spine* 2000;25:923–8.
- [59] Heini PF, Orler R. Vertebroplastik bei hochgradiger Osteoporose Technik und Erfahrung mit plurisegmentalen Injektionen. *Orthopade* 2004;33:22–30.
- [60] Lindsay R, Silverman SL, Cooper C, Hanley DA, Barton I, Broy SB, et al. Risk of new vertebral fracture in the year following a fracture. *J Am Med Assoc* 2001;285:320–3.
- [61] Ross PD, Genant HK, Davis JW, Miller PD, Wasnich RD. Predicting vertebral fracture incidence from prevalent fractures and bone density among non-black, osteoporotic women. *Osteoporos Int* 1993;3:120–6.