

An *In Vivo* Comparison of the Potential for Extravertebral Cement Leak After Vertebroplasty and Kyphoplasty

Frank M. Phillips, MD,* F. Todd Wetzel, MD,* Isadore Lieberman, MD,† and
Marrion Campbell-Hupp, RN*

Study Design. A prospective *in vivo* study was conducted during the performance of kyphoplasty for the treatment of osteoporotic vertebral compression fractures, comparing extravertebral contrast extravasation with kyphoplasty and vertebroplasty.

Objective. To determine the frequency and pattern of extravertebral contrast extravasation after intravertebral injection during kyphoplasty and vertebroplasty, which have implications for cement leakage during these procedures.

Summary of Background Data. Vertebroplasty involves the injection of cement directly into the cancellous bone of a fractured vertebral body in an attempt to stabilize the fracture. High rates of extravertebral cement leakage have been noted. Injection of contrast into the vertebral body under fluoroscopy has been recommended in an attempt to predict and minimize cement leakage. An alternative procedure, balloon kyphoplasty, involves the percutaneous placement of an inflatable bone tamp into the fractured vertebral body. As the tamp is inflated, vertebral body height is restored and a cavity is created within the vertebral body, allowing for low-pressure cement filling of the cavity.

Methods. During 20 kyphoplasty surgeries for vertebral compression fractures, contrast studies were performed. Immediately after positioning of an 11-gauge biopsy needle within the midvertebral body, 5 mL of Omnipaque was injected, mimicking vertebroplasty injection. Cinefluoroscopic images were obtained during injection. After bilateral fracture reduction and intravertebral cavity creation using inflatable bone tamps (kyphoplasty), contrast was injected again, mimicking cement injection during kyphoplasty. Scoring of the extravertebral contrast leakage was based on filling of the inferior vena cava and epidural vessels, as well as direct contrast extension through the vertebral cortex.

Results. The mean contrast leak scores for vertebroplasty- and kyphoplasty-stage injections were, respectively, 4.3 and 0.8 of 6 ($P = 0.0001$). The scores for epidural vessel and inferior vena cava filling and transcortical contrast leak

each was significantly lower for kyphoplasty- than for vertebroplasty-stage injections ($P = 0.0001$ each).

Conclusions. The findings showed less vascular and transcortical extravasation of injected contrast with kyphoplasty than with vertebroplasty. Although leakage of contrast may not correlate precisely with polymethylmethacrylate leakage, the authors believe this study highlights the relative safety of these procedures. [Key words: contrast extravasation, kyphoplasty, osteoporotic vertebral fracture, safety, vertebroplasty] **Spine 2002;27:2173-2179**

Osteoporotic vertebral compression fractures (VCFs) represent a significant cause of morbidity and disability in the elderly.^{3,13,14,16,21,27,28} The consequences of VCFs include pain related to the fracture, and in many cases progressive collapse of the fractured osteopenic vertebral body leading to spinal kyphosis. Spinal kyphosis as a result of osteoporotic VCFs has been shown to have an adverse effect on quality of life, physical function, mental health, and survival.^{3,13,14,18,27,28,30,31} These effects are related to the severity of the spinal deformity,^{3,13,14,28} and are at least partly independent of pain.^{13,15}

Ideally, the treatment of osteoporotic vertebral compression fractures should address both fracture-related pain and the kyphotic deformity in a minimally invasive fashion. Over the past decade, vertebroplasty involving the percutaneous injection of polymethylmethacrylate (PMMA) directly into a fractured vertebral body has been used for the treatment of osteopenic VCFs. Substantial pain relief has been reported in a majority of patients treated with vertebroplasty. However, vertebroplasty does not address the associated spinal deformity.^{4,5,7-9,11,12} Kyphoplasty is a minimally invasive orthopedic procedure designed to address both the kyphotic deformity and the fracture pain. It involves the percutaneous insertion of an inflatable bone tamp into a fractured vertebral body under fluoroscopic guidance. Inflation of the bone tamp elevates the endplates, restoring the vertebral body toward its original height while creating a cavity to be filled with bone void filler. Early results of kyphoplasty suggest significant pain relief as well as ability to improve the height of the collapsed vertebral body and reduce spinal kyphosis.^{10,17,24,32}

During vertebroplasty, cement is forcibly injected directly into the cancellous bone of a collapsed vertebral body. This requires high-pressure injection of low-viscosity cement, which introduces the risk of cement

From the *University of Chicago Spine Center, Chicago, Illinois, and the †Department of Orthopaedics, Cleveland Clinic, Cleveland, Ohio. Acknowledgment date: November 27, 2001.

First revision date: February 15, 2002.

Acceptance date: March 4, 2002.

Device Status/Drug Statement: The devices and drugs that are the subject of this manuscript are not FDA-approved for this indication and are not commercially available in the United States.

Conflict of Interest: No funds were received in support of this work. One or more of the authors have received or will receive benefits (e.g., honoraria, gifts, consultancies, royalties, stocks, stock options, decision-making position) for personal or professional use from a commercial party related directly or indirectly to the subject of this manuscript.

DOI: 10.1097/01.BRS.0000025689.39941.26

extravasating beyond the confines of the vertebral body. Extravertebral cement leakage has been reported to occur in up to 65% of vertebra treated with vertebroplasty.⁵ In an attempt to reduce the risks of vertebroplasty cement-related complications, it has been recommended that before cement injection, intravertebral contrast injection under fluoroscopy should be performed.¹² If contrast is seen to leak outside of the vertebral body, particularly into the spinal canal or venous system, repositioning of the cement-injecting tool is recommended. Kyphoplasty, by virtue of creating an intravertebral cavity surrounded by compacted cancellous bone resulting from IBT inflation, allows for low-pressure filling of the cavity with viscous cement, which might reduce the risks of extravertebral extravasation.^{1,2,17}

This study aimed to test the hypothesis that kyphoplasty reduces the potential for extravertebral filler extravasation, as compared with vertebroplasty. Intravertebral contrast injection under live fluoroscopy has been recommended for assessing cement leakage potential.¹² This technique was used to compare potential for filler leakage after kyphoplasty (reduction of fracture and cavity creation with inflatable bone tamp) and vertebroplasty (direct cement injection into a collapsed vertebra).

Methods

For this study, 20 consecutive patients with painful osteopenic VCFs between T7 and L4 underwent kyphoplasty, and vascular studies were analyzed. The mean patient age was 73.5 years (range, 51–90 years). The VCF was confirmed as the pain source by combining clinical examination with radiographic studies. In all cases, MRI was used to document change in bone marrow signal intensity in the vertebral body consistent with an acute or nonhealed vertebral fracture. The mean age of the treated fracture was 4.5 months.

All kyphoplasty procedures were performed in the operating room with the patient under conscious sedation or general anesthesia. The patients were positioned prone, and biplane fluoroscopy was used throughout the procedure. An 11-gauge Jamshidi needle was placed percutaneously into the vertebral body through either a trans- or extrapedicular approach, as described previously for vertebroplasty.^{8,12} The needle typically was placed into the middle one third of the vertebral body. A 10-mL syringe filled with contrast (Omnipaque) was attached to extension tubing, which was flushed with contrast. The tubing then was attached to the hub of the Jamshidi needle and 5 mL of Omnipaque was injected into the vertebral body under live lateral continuous fluoroscopy. This injection simulated contrast injection that might be performed before cement injection during vertebroplasty. All radiographic images were stored for subsequent review. The intravertebral contrast then was flushed out of the vertebral body with saline injection.

Next, kyphoplasty was performed in standard fashion. The biopsy needles were exchanged over a guidewire for a working cannula. Inflatable bone tamps (IBTs) (Kyphon Inc., Sunnyvale, CA) then were placed into the vertebral body through bilateral working cannulas. The IBTs were inflated using visual (fluoroscopic) and manometric parameters until vertebral body height was restored, they contacted a vertebral body cortical

Table 1. Contrast Scores With Vertebroplasty and Kyphoplasty-Stage Injections

	Vertebroplasty Stage	Kyphoplasty Stage
Inferior Vena Cava*	1.7	0.4‡
Epidural vein*	1.7	0.2‡
Transcortical leak*	1.0	0.2‡
Total "leakage score"†	4.3	0.8‡

* Mean score out of maximum of 2 points (0 = no; 1 = faint; 2 = intense contrast).

† Mean total score (maximum of 6 points).

‡ $P = 0.0001$.

wall, or reached a pressure of 220 psi or the maximal balloon volume. The IBTs then were withdrawn, and the kyphoplasty bone-filler tool (BFT), a hollow cannula used for cement insertion during kyphoplasty, with extension tubing attached to the hub was positioned in the resultant intravertebral cavity. Using fluoroscopic guidance, the tip of the BFT was placed in the same position as the tip of the Jamshidi needle during the initial contrast injection. Thereafter, 5 mL of Omnipaque was injected into the vertebral body under continuous live lateral fluoroscopy. All fluoroscopic images were stored for subsequent review. Kyphoplasty was completed after cement had been placed into the cavity of the fractured vertebral body.

Image Analysis. Cine and still fluoroscopic images obtained during and immediately after injection of 5 mL of Omnipaque at the vertebroplasty- and kyphoplasty-stage of the procedure were studied. Two spine surgeons not involved in the surgical procedures scored these images independently. The authors had planned on having a third reviewer grade the images for which the opinions of the first two reviewers varied, but this was not necessary. Images were reviewed for evidence of direct extravasation of contrast through the vertebral cortex filling the inferior vena cava and epidural veins with contrast. Each of these findings was graded as 0 (absent), 1 (mildly positive), or 2 (strongly positive). A "leak score" for each level treated was calculated by adding the individual scores in each category (total, 6 points). Statistical analysis of these scores was performed using the paired *t* test with significance set at a *P* value less than 0.05.

Results

The mean total contrast leak scores for vertebroplasty and kyphoplasty contrast injections were, respectively, 4.3 versus 0.8 of 6 ($P = 0.0001$) (Table 1). The scores for epidural, IVC, and transcortical contrast leak each was significantly lower for kyphoplasty- than for vertebroplasty-stage injections ($P = 0.0001$ for each).

For no vertebroplasty contrast injection did the contrast remain confined to the vertebral body. With vertebroplasty injection, direct extravasation of contrast through a vertebral cortex was seen in 14 of 20 studies, including extravasation through the posterior vertebral cortex in 5 studies (Table 2). With vertebroplasty injections, almost immediate filling of the foraminal and then the epidural veins occurred, with almost simultaneous filling of the segmental veins (Figures 1 and 2). Opacification of IVC with contrast was visualized in 19 of 20 injection studies, and considered "strongly" positive in

Table 2. Scores for Extravertebral Contrast Extravasation With Vertebroplasty and Kyphoplasty

Patient	Fracture Level	Vertebroplasty				Kyphoplasty			
		IVC*	Epi*	EV*	Total†	IVC*	Epi*	EV*	Total†
1	L3	2	2	1	5	1	0	0	1
2	L1	2	2	0	4	0	0	0	0
3	L3	2	1	0	3	0	0	0	0
4	T11	1	2	0	3	1	2	0	3
5	T12	2	2	1	5	0	1	0	1
6	T11	1	1	1	3	0	0	1	1
7	T10	1	0	2	3	1	0	2	3
8	L1	2	2	2	6	1	0	0	1
9	L2	2	2	2	6	0	0	0	0
10	T8	2	2	2	6	1	0	0	1
11	L3	0	2	2	4	1	0	0	1
12	T12	2	2	1	5	0	0	0	0
13	L2	2	2	1	5	1	0	0	1
14	T11	2	1	0	3	1	1	0	2
15	T8	2	1	1	4	0	0	0	0
16	T11	1	2	1	4	0	0	0	0
17	L2	2	2	1	5	0	0	0	0
18	T12	2	2	0	4	0	0	0	0
19	T7	2	2	0	4	1	0	0	1
20	L1	2	2	1	5	0	1	0	1

* Mean score out of maximum of 2 points (0 = no; 1 = faint; 2 = intense contrast).

† Mean total score (maximum of 6 points).

IVC = inferior vena cava; Epi = epidural veins, EV = extravertebral-transcortical.

15 studies. Epidural vein filling with contrast (19 of 20 injections) was confined to the area between the pedicles of the vertebral level proximal and distal to the treated vertebra. Contrast filling of segmental veins was seen up to three vertebral levels away from the injection site. The contrast leak pattern was similar at the thoracic and lumbar vertebral levels.

With contrast injection after fracture reduction and cavity creation using the IBT (kyphoplasty), contrast tended to collect in the cavity created in the vertebral body. Extravertebral extravasation of contrast occurred toward the end of the injection when the volume of contrast injected exceeded the volume of the cavity created by the IBT. In 8 of 20 kyphoplasty studies, no extravertebral contrast was seen. With kyphoplasty injection, direct extravasation of contrast through the posterior vertebral cortex was seen in one study. Opacification of IVC occurred in 9 of 20 kyphoplasty injections, and in all cases the fill was considered "mildly" positive, occurring toward the end of the contrast injection. In all cases, the extent of IVC opacification was less extensive with kyphoplasty than with the corresponding vertebroplasty injection (scores 0.4 and 1.07, respectively; $P = 0.001$). Epidural vein filling was seen in three kyphoplasty injection studies. In one case wherein a kyphoplasty contrast injection showed extravasation of contrast into the disc space, cement also entered the disc space during cementing. No epidural cement was seen on the intra- or post-operative radiographs of any kyphoplasty procedure. To ensure that vascular spasm induced by the initial vertebroplasty injection was not an explanation for the diminished egress of contrast with kyphoplasty injection, ky-

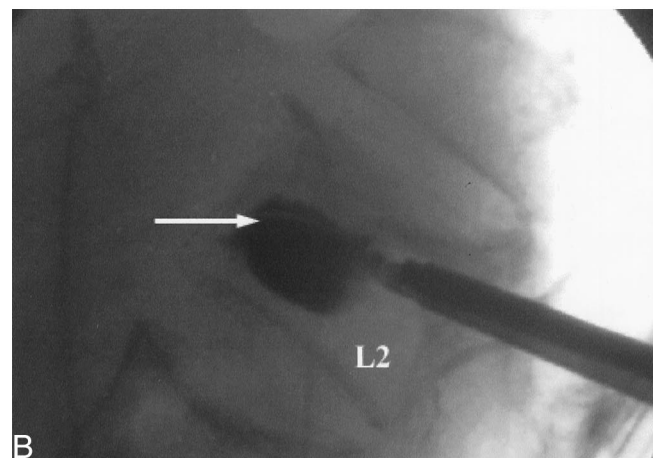
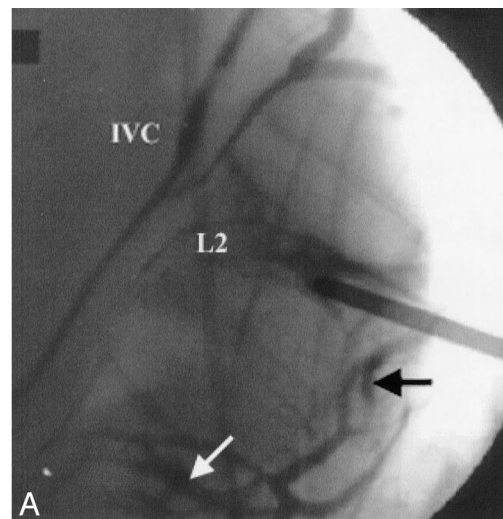


Figure 1. **A**, L2 vertebroplasty contrast injection, with contrast filling the IVC, epidural vessels (black arrow), and segmental vessels (white arrow). **B**, L2 kyphoplasty contrast injection, with contrast confined to the intravertebral cavity (arrow).

phoplasty studies without prior injections also were performed. In these kyphoplasty-only contrast studies, a similar pattern of intravertebral containment of contrast was seen.

Discussion

During vertebroplasty and kyphoplasty, bone filler is introduced into a fractured vertebral body in an attempt to stabilize the fracture. For vertebral augmentation procedures, PMMA has been the most widely used bone filler, and most of the serious complications reported are related to leakage of PMMA outside the confines of the vertebral body during injection.^{5,6,8,20,23} The PMMA may exit the vertebral body through deficiencies or fractures in the vertebral cortex or by injection of cement into the vertebral venous system.^{11,12,20} Leakage of cement through the vertebral cortex may result in direct injury to or compression of adjacent structures such as the spinal cord. When injected cement enters the venous system, there is the potential for cement to fill the epidural veins and cause spinal cord or nerve root compres-

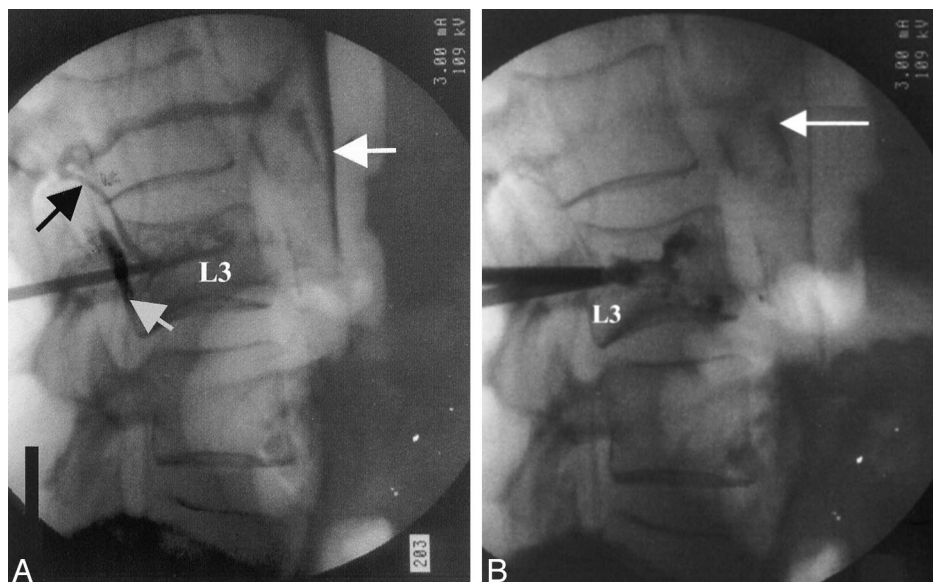


Figure 2. **A**, L3 vertebroplasty contrast injection with dense contrast filling the IVC (white arrow) and foraminal vessels (black arrow), and leaking into the spinal canal (short arrow). **B**, L3 kyphoplasty contrast injection with faint contrast filling of the IVC (arrow) without an intracanal contrast leak.

sion, or for PMMA pulmonary embolism.^{11,12,20} In addition, high-pressure intraosseous injection of cement may lead to embolization of methylmethacrylate monomer and bone marrow contents of the lungs, with negative cardiopulmonary sequelae.^{19,22,23,25,26,29} Pressurization of PMMA during joint arthroplasty surgery has been associated with the occasional cardiovascular collapse.^{22,25,26}

During vertebroplasty, the high-pressure injection of low-viscosity cement directly into cancellous bone makes it difficult to control the cement flow in the vertebral body, thus creating an unpredictable risk of cement extravasation outside the vertebral body. In fact, extravertebral cement extravasation commonly is seen during vertebroplasty. However, proponents of this technique have reported infrequent clinical sequelae of the leakage. Cotten et al⁶ noted 15 epidural cement leaks, 8 intradiscal leaks, 2 venous leaks, and 21 paravertebral leaks in 20 of 37 patients (40 fractures) treated with vertebroplasty. Two of the foraminal leaks required decompressive surgery, and one soft tissue femoral neuropathy was treated with steroids. Cortet et al⁵ reported extravertebral cement in 13 of 20 vertebra (65%) treated with vertebroplasty for osteoporotic fractures. Cement leaked into the paravertebral soft tissues in six cases, into the peridural space in three cases, into the disc space in three cases, and into the lumbar venous plexus in one patient. Cyteval et al⁷ noted extravertebral cement in 8 of 20 patients after vertebroplasty, with leakage into the intervertebral disc in 5 patients, into the neural foramen in 2 patients, and into the lumbar venous plexus in 1 patient. Deramond⁸ reported radiculopathy in 4% of patients undergoing vertebroplasty, likely related to intraforaminal cement leakage, noting "frequent leaks of PMMA into the perivertebral veins."

Reports of serious complications related to extravertebral cement extravasation during vertebroplasty also have been presented. A recent study reported that 3 of 35

patients treated with vertebroplasty had extravasation of cement into the epidural space, necessitating open surgical decompression in two patients.²⁰ In this study, an additional two patients had cement pulmonary emboli. Additional cases of symptomatic and lethal PMMA pulmonary embolism with vertebroplasty have been reported.^{11,12,23}

Kyphoplasty represents an attempt to address the shortcomings of vertebroplasty (*i.e.*, inability to correct spinal deformity and high-pressure injection of cement into the fractured vertebral body). During kyphoplasty, the creation of an intravertebral cavity with the IBTs (Figure 3) allows for a range of filler options, with placement under lower pressure. In addition, the IBT compacts the trabecular bone, which may seal potential osseous or venous leak paths. When PMMA is used, it can

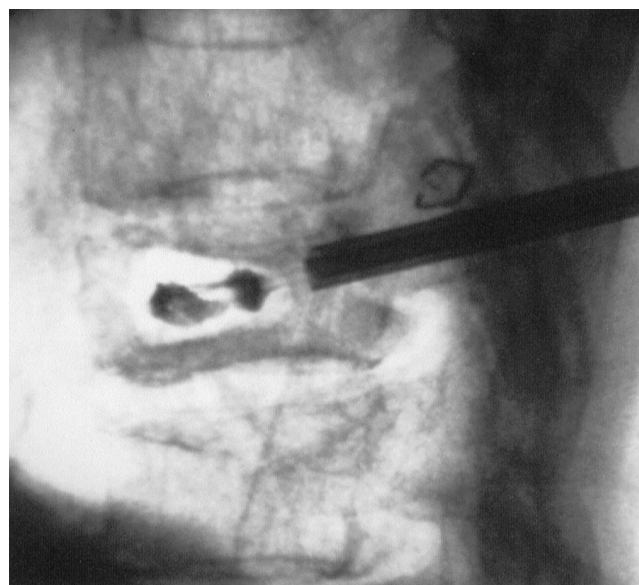


Figure 3. Intravertebral cavity created during T12 kyphoplasty, with balloon tamp partially deflated.

be placed partially cured (viscous) into the created cavity, which also may reduce the risk of leakage. Cadaver and clinical studies support the reduced leak rate with kyphoplasty. Belkoff et al¹ reported extravertebral PMMA (Simplex P) leakage in 5 of 8 fractured human cadaveric vertebral bodies treated with vertebroplasty, with no cement leakage seen in fractured vertebra treated with kyphoplasty. In a similar cadaver model, Belkoff et al reported that when vertebroplasty was performed with cements of varying material behaviors, cement leaks occurred in 8 of 12 treated vertebral bodies.² In a clinical Phase 1 efficacy study, Lieberman et al¹⁷ reported on 30 patients who had osteopenic VCFs treated with kyphoplasty at 70 vertebral levels and noted extravertebral cement leakage at six levels (8.6%). No neurologic complications occurred. In a report of the initial 1471 VCFs treated with kyphoplasty in the United States, only one case of neurologic compromise related to cement intrusion into the spinal canal or neural foramen was described.¹⁰

With vertebroplasty contrast injection, contrast was seen to leak through the vertebral cortex in 60% of injections, raising a concern for direct PMMA leakage outside the bony spine. Proponents of vertebroplasty, recognizing this risk, have recommended that the operator cease further injection of cement once it is evident that cement has passed outside the vertebra. In reality, the reaction time from visualization of the cement leakage until cessation of injection may not be short enough to eliminate cement leak. Premature cessation of cement injection also may lead to inadequate cement filling of the vertebra.

With vertebroplasty, contrast invariably filled the vertebral venous circulation, with flow into the epidural veins, the segmental veins, and the inferior vena cava. After creation of an intravertebral cavity with the IBT, the risk of vascular filling was significantly reduced. These findings have potential implications not only for cement extravasation, but also for cement monomer passage into the circulation. It seems likely that the soluble PMMA monomer would have vascular egress from the vertebral body similar to that of the water-soluble contrast used in the current study. Systemic PMMA monomer exposure, with its deleterious effects on cardiopulmonary function, may have clinical implications in this elderly patient population.^{19,22,23,25,26}

The current study was limited in that extravertebral leakage of contrast does not correlate precisely with cement leakage. The authors, however, believe that the study proposes a reasonable technique for evaluating the relative risks of leakage during vertebral augmentation procedures using a recommended imaging technique.¹² This is further supported by a recent study by McGraw et al,^{19A} who reported that intraosseous venography predicted the subsequent flow of PMMA during vertebroplasty in 83% of cases. Although the escape of contrast after intravertebral injection creates a “worse case scenario” for leakage during vertebral augmentation proce-

dures, the ready egress of contrast into the venous system raises the concern that with pressurized cement injection, cement monomer will enter the circulation. This concern should prompt caution when these procedures are performed in elderly patients with cardiopulmonary compromise or when multilevel vertebral cement injections are performed. When vertebral augmentation with PMMA is performed, appropriate monitoring and resuscitative equipment, expertise, and ability for management of complications resulting from extravertebral cement extravasation should be available.

Vertebral augmentation procedures are being used increasingly in the treatment of painful osteoporotic vertebral fractures. The current study highlights the potential for extravertebral cement leakage with these procedures, supporting the conclusion from the clinical data that kyphoplasty, by virtue of the created intravertebral cavity, lowers the potential for filler leakage, as compared with vertebroplasty.

■ Key Points

- Most of the complications reported with vertebral augmentation procedures used to treat osteopenic vertebral compression fractures are the result of extravertebral cement extravasation.
- Vertebroplasty, involving injection of cement into the fractured vertebral body, results in extravertebral cement leakage in up to 65% of treated levels.
- Kyphoplasty involves the inflation of a percutaneously placed bone tamp in the fractured vertebral body to create an intravertebral cavity allowing for low-pressure packing of cement in the cavity.
- With intravertebral contrast injections during kyphoplasty, significantly lower extravertebral (epidural, IVC, and transcortical) contrast leak scores were noted than with vertebroplasty injections.

References

1. Belkoff SM, Mathis JM, Fenton DC, et al. An *ex vivo* biomechanical evaluation of an inflatable bone tamp used in the treatment of compression fracture. *Spine* 2001;26:153–6.
2. Belkoff SM, Mathis JM, Jasper LE, et al. An *ex vivo* biomechanical evaluation of a hydroxyapatite cement for use with vertebroplasty. *Spine* 2001;26:1542–6.
3. Cook DJ, Guyatt GH, Adachi JD, et al. Quality of life in women with vertebral fractures due to osteoporosis. *Arthritis Rheum* 1993;36:750–6.
4. Cortet B, Cotton A, Boutry N, et al. Percutaneous vertebroplasty in patients with osteolytic metastases or multiple myeloma. *Rev Rhum* 1997;64:177–83.
5. Cortet B, Cotton A, Boutry N, et al. Percutaneous vertebroplasty in the treatment of osteoporotic vertebral compression fractures: An open prospective study. *J Rheum* 1999;26:2222–8.
6. Cotten A, Dewatre F, Cortet B, et al. Percutaneous vertebroplasty for osteolytic metastases and myeloma: Effects of the percentage of lesion filling and the leakage of methyl methacrylate at clinical follow-up. *Radiology* 1996;200:525–30.
7. Cyteval C, Sarrabere MPB, Roux JO, et al. Acute osteoporotic vertebral

- collapse: An open study of percutaneous injection of acrylic cement in 20 patients. *AJR Am J Roentgenol* 1999;173:1685-90.
8. Deramond H, Depriester C, Galibert P, et al. Percutaneous vertebroplasty with polymethylmethacrylate. *Radiol Clin North Am* 1998;36(3):533-46.
 9. Gangi A, Kastler BA, Dietmann JL. Percutaneous vertebroplasty guided by a combination of CT and fluoroscopy. *Am J Neuroradiol* 1994;15:83-6.
 10. Garfin SR, Yuan H, Reiley MA. New technologies in spine: Kyphoplasty and vertebroplasty for the treatment of painful vertebral body compression fractures. *Spine* 2001;26:1511-15.
 11. Grados F, Depriester C, Cayrolle G, et al. Long-term observations of vertebral osteoporotic fractures treated by percutaneous vertebroplasty 2000;39:1410-14.
 12. Jensen ME, Evans A, Mathis JM, et al. Percutaneous polymethylmethacrylate vertebroplasty in the treatment of osteoporotic vertebral body compression fractures: Technical aspects. *AJNR Am J Neuroradiol* 1997;18:1897-904.
 13. Kado DM, Browner WS, Palermo L, et al. Vertebral fractures and mortality in older women: A prospective study. *Arch Int Med* 1999;159:1215-20.
 14. Leech JA, Dulberg C, Kellie S, et al. Relationship of lung function to severity of osteoporosis in women. *Am Rev Resp Dis* 1990;14:68-71.
 15. Leidig-Bruckner G, Minne HW, Schlaich C, et al. Clinical grading of spinal osteoporosis: Quality of life components and spinal deformity in women with chronic low back pain and women with vertebral osteoporosis. *J Bone Miner Res* 1997;12:663-75.
 16. Leidig G, Minne HW, Sauer P, et al. A study of complaints and their relation to vertebral destruction in patients with osteoporosis. *Bone Miner* 1990;8:217-29.
 17. Lieberman IH, Dudeney S, Reinhardt M-K, et al. Initial outcome of "kyphoplasty" in the treatment of painful osteoporotic vertebral body compression fractures. *Spine* 2001;26:1631-6.
 18. Lyles KW, Gold DT, Shipp KM, et al. Association of osteoporotic vertebral compression fractures with impaired function status. *Am J Med* 1993;94:595-601.
 19. Markel DC, Femino JE, Farkas P, et al. Analysis of lower extremity embolic material after total knee arthroplasty in a canine model. *J Arthroplasty* 1999;14:227-32.
 - 19A. McGraw JK, Heatwole EV, Strnad BT, et al. Predictive value of intraosseous venography before percutaneous vertebroplasty. *J Vase Intervent Radiol* 2002;13:149-53.
 20. Moreland DB, Landi MK, Grand W. Vertebroplasty: Techniques to avoid complication. *Spine J* 2001;1:65-70.
 21. Nevitt MC, Ettinger B, Black DM, et al. The association of radiographically detected vertebral fractures with back pain and function: A prospective study. *Ann Int Med* 1998;128:793-800.
 22. Orsini EC, Byrick RJ, Mullen JB, et al. Cardiopulmonary function and pulmonary microemboli during arthroplasty using cemented or noncemented components: The role of intramedullary pressure. *J Bone Joint Surg Am* 1987;69:822-32.
 23. Padovani B, Kasriel O, Brunner P, et al. Pulmonary embolism caused by acrylic cement: A rare complication of percutaneous vertebroplasty. *AJNR Am J Neuroradiol* 1999;20:375-7.
 24. Phillips FM, McNally T. Early clinical and radiographic results for kyphoplasty in the treatment of osteopenic vertebral compression fractures. *Proc ISSLS* 2001;228.
 25. Pinto PW. Cardiovascular collapse associated with the use of methacrylate. *AANA J* 1993;61:613-6.
 26. Pitto RP, Blunk J, Kossler M. Transesophageal echocardiography and clinical features of fat embolism during cemented total hip arthroplasty: A randomized study in patients with femoral neck fractures. *Arch Orthop Trauma Surg* 2000;120:53-8.
 27. Pluijm SMF, Tromp AM, Smit JH, et al. Consequences of vertebral deformities in older men and women. *J Bone Miner Res* 2000;15:1564-72.
 28. Ross PD, David JW, Epstein RS, et al. Pain and disability associated with new vertebral fractures and other spinal conditions. *J Clin Epidemiol* 1994;47:234-9.
 29. Rudigier JF, Ritter G. Pathogenesis of circulatory reactions triggered by nervous reaction during the implantation of bone cements. *Res Exp Med* 1983;183:77-94.
 30. Schlaich C, Minne HW, Bruckner T, et al. Reduced pulmonary function in patients with spinal osteoporotic fractures. *Osteoporos Int* 1998;8:261-7.
 31. Silverman SL. The clinical consequences of vertebral compression fracture. *Bone* 1992;13:27-31.
 32. Wong W, Reiley MA, Garfin S. Vertebroplasty/kyphoplasty. *J Womens Imaging* 2000;2:117-24.

Address reprint requests to

Frank M. Phillips, MD
 University of Chicago Spine Center
 4646 North Marine Drive
 Chicago, IL 60640
 E-mail: fbphillip@weissshospital.org

Point of View

John D. Barr, MD
 Center for Neuroendovascular Surgery
 Baptist Memorial Hospitals
 Mid South Imaging and Therapeutics
 Memphis, Tennessee

Whether performed with or without venography, the safety of percutaneous vertebroplasty has been well demonstrated by the experience of numerous groups in Europe and the United States. Although there is less experience with kyphoplasty, the derivative technique, it too

appears to be a safe technique. Serious complications rarely are reported with either technique.

I disagree with the authors' conclusion that more prominent venous opacification is seen with contrast injected before vertebroplasty than with injection of contrast into the cavity created by the inflatable bone tamps during kyphoplasty, portending a high risk for subsequent extraosseous and vascular cement leakage. If a sufficient volume of contrast is injected into a vertebral body, opacification of the epidural, perivertebral, and central veins results. Those of us who pioneered the vertebroplasty technique in the United States have

Device Status/Drug Statement: The devices and drugs that are the subject of this manuscript are not FDA-approved for this indication and are not commercially available in the United States.

Conflict of Interest: No funds were received in support of this work. No benefits in any form have been or will be received from a commercial party related directly or indirectly to the subject of this manuscript.

DOI: 10.1097/01.BRS.000025690.68214.81

subsequently recognized that intraosseous venography does not accurately depict the distribution of injected cement.²⁻⁴ Most of us have abandoned the use of venography except as a teaching tool or perhaps when treating hypervascular tumors.

Symptomatic cement leakage is a rare complication for either vertebroplasty or kyphoplasty performed to manage benign osteoporotic fractures. With vertebroplasty, symptomatic cement leakage is recognized to be more frequent in the management of neoplastic disease, as compared with osteoporosis. The results reflect the treatment of osteolytic lesions that have already breached the cortex of the vertebrae. Vertebral corpectomy and reconstructive instrumentation for the treatment of such malignant spinal column lesions also are not without significant risk and morbidity. None of the initial reports on kyphoplasty described significant experience with treatment of neoplastic lesions. Currently, there is insufficient knowledge and experience with kyphoplasty used to treat neoplastic diseases to determine whether the results are similar to those in the initial experience with osteoporosis.

Small, asymptomatic cement leaks are of no clinical consequence with either treatment method. Dr. Lieberman was one of the authors of the American College of Radiology Standard for the Performance of Percutaneous Vertebroplasty,¹ which recognizes that such small asymptomatic cement leaks do not affect patient outcomes, and do not represent a complication of treatment. The literature suggests that such leaks may be more frequent with vertebroplasty than with kyphoplasty. This suggestion may reflect the numerous reports of vertebroplasty that included posttreatment evaluation with CT, which can detect tiny cement leaks that would not be evident from simple radiographs. The initial reports describing the results of kyphoplasty have not included posttreatment CT imaging, which also might show small asymptomatic cement leaks. In any case, small, asymptomatic cement leaks are of no importance.

Although the authors claim their venography technique is the identical to that advocated for the performance of vertebroplasty, the needle positions used to place the inflatable bone tamps differ slightly, but significantly, from those used to perform vertebroplasty. The basivertebral vein is located in the midportion of the vertebral body. This vein leads directly to the anterior

internal venous plexus within the spinal canal. Cement injected into the basivertebral vein may easily reach the spinal canal *via* this pathway. To minimize this risk during the performance of vertebroplasty, needles are positioned to avoid the central area of the vertebral body. Placement of two needles in the lateral aspects of the vertebra or placement of a single needle in the far anterior midline of the vertebral body is customary.

For the performance of kyphoplasty, the needles must be positioned in the central vertebral body because this is the proper location for inflation of the bone tamps. Venography performed with the needles positioned in the central vertebral body therefore will show much more direct filling of the basivertebral vein and anterior internal venous plexus than would be expected with the anterior or lateral needle placement used for vertebroplasty. Therefore, the authors' venograms are not truly identical to those that would be obtained during vertebroplasty with traditional needle positioning.

Most importantly, whether venography actually predicts potential areas for cement leakage during vertebroplasty remains highly doubtful. Decreased visualization of venous structures when "cavity grams" are performed before cement injection during kyphoplasty should not be construed to imply greater safety of kyphoplasty.

The main proponents of kyphoplasty, many of whom have significant financial interests, continue to argue for the superiority of this technique relative to vertebroplasty. Currently, the published clinical outcomes of both techniques used to treat patients with osteoporotic fractures are not significantly different. The cost for patients treated by kyphoplasty is much greater. The clinical utility of partial height restoration and kyphosis reduction achievable in some patients treated with kyphoplasty remains to be proved.

References

1. Barr JD, Mathis JM, Barr MS, et al. American College of Radiology Standard for the Performance of Percutaneous Vertebroplasty. Reston, VA: ACR, 2001: 345-52.
2. Do HM. Intraosseous venography during percutaneous vertebroplasty: Is it needed? *AJNR Am J Neuroradiol* 2002;23:508-9.
3. Gaughen JR Jr, Jensen ME, Schweickert PA, et al. Relevance of antecedent venography in percutaneous vertebroplasty for the treatment of osteoporotic compression fractures. *AJNR Am J Neuroradiol* 2002;23:594-600.
4. Wong W, Mathis JM. Is intraosseous venography a significant safety measure in performance of vertebroplasty? *J Vasc Interv Radiol* 2002;13:137-8.