

# PediGuard™: A Solution for the Challenges of Pedicle Screw Placement

RANDAL R. BETZ, MD,<sup>1</sup> AMER F. SAMDANI, MD,<sup>1</sup> MLADEN DJURASOVIC, MD,<sup>2</sup>  
STEWART I. BAILEY, MD,<sup>3</sup> COURTNEY BROWN, MD,<sup>4</sup> JAHANGIR ASGHAR, MD,<sup>1</sup>  
LINDA P. D'ANDREA, MD,<sup>5</sup> JOHN DIMAR, MD,<sup>6</sup>  
HARRY L. SHUFFLEBARGER, MD,<sup>7</sup> JOHN GAUGHAN, PHD<sup>8</sup>

<sup>1</sup>Shriners Hospitals for Children, Philadelphia, PA, <sup>2</sup>Leatherman Spine Center, Louisville, KY,

<sup>3</sup>Westminster Hospital, London, Ontario, Canada, <sup>4</sup>Panorama Orthopedics and Spine Center, Golden, CO,

<sup>5</sup>Brandywine Institute of Orthopaedics, Pottstown, PA,

<sup>6</sup>Department of Orthopaedic Surgery, University of Louisville, Louisville, KY, <sup>7</sup>Miami Children's Hospital, Miami, FL,

<sup>8</sup>Department of Biostatistics, Temple University School of Medicine, Philadelphia, PA

*Conflict of interest statement: Supported by a research grant from SpineVision, Inc.*

### Abstract

Pedicle screw fixation is not without complications, one of which is pedicle perforation, with rates ranging as high as 40%. Much of the variation in perforation rates in the literature depends on the method used to determine the perforation. Studies using a postoperative CT scan reviewed by independent or blinded reviewers show higher rates of perforation than those determined by radiograph. Despite all of the available techniques used to minimize perforation, there is still a need for an efficient, simple, and cost effective device which will help the surgeon to more safely drill a pilot hole for placement of a pedicle screw. In a US clinical randomized trial, preliminary analysis of patients having had surgery for degenerative conditions with titanium screws between T12 and S1 shows a significant clinical trend in reduction of breach (by 8%) using the PediGuard™ device and a six-fold reduction in medial breaches. In a separate cohort of patients comparing PediGuard™ and a fluoroscopic technique, the average radiation exposure was reduced by approximately 30% with PediGuard™.

### Introduction

Pedicle screw fixation has been shown to be superior to other methods of instrumentation of the spine for spinal fusion and correction of spine deformity.<sup>4, 7, 9-11, 15, 18, 20</sup> In a meta-analysis of the literature by Yahiro<sup>22</sup> of 5,756 patients reported in 101 articles, the success of fusions with pedicle screws was 94.8%, attesting to the clinical usefulness of this technique.

Pedicle screw fixation is not without complications, one of which is pedicle perforation, with rates ranging as high as 40%.<sup>1</sup> Perforations can further lead to complications such as

dural tear,<sup>19</sup> nerve root injuries,<sup>19</sup> paraplegia,<sup>6, 16, 19, 23</sup> or vascular injury.<sup>8</sup>

Much of the variation in perforation rates in the literature depends on the method used to determine the perforation. Studies using a postoperative CT scan reviewed by independent or blinded reviewers show higher rates of perforation than those determined by radiograph.

Many surgeons rely on plain radiographs to assess screw perforation postoperatively. However, the number of malpositioned screws are underestimated. In an article by Leach, et al.<sup>13</sup> using cadaver specimens of the lumbar spine, only 63% of the screw positions were correctly identified on radiograph as compared to 87% with CT scan.

When inserting screws in the pedicle, surgeons rely on various methods to ensure accurate placement. The gold standard is manual probing, often with or without fluoroscopy. The "freehand technique" is based on knowledge of spinal anatomy.<sup>14</sup> This technique results in the least radiation exposure to the patient and surgeon but is less accurate in placing contained pedicle screws as compared to imaging techniques.<sup>12</sup>

A fluoroscopic technique may provide more consistent results but carries some risks associated with radiation dose, especially to young patients<sup>17, 21</sup> and to the surgeon.<sup>21</sup>

Three dimensional image-guided surgery (IGS) can result in better screw accuracy. Surgeons have also used various electrophysiological monitoring techniques such as EMG and somatosensory evoked potentials (SEP) for assessing nerve root function and pedicle screw placement.<sup>12, 17</sup> Clements, et al.<sup>5</sup> report thresholds above 10 mA as being associated with no postoperative nerve root radiculopathies.

Despite all of the above mentioned techniques, there is still a need for an efficient, simple, and cost effective device which will help the surgeon to more safely drill a pilot hole for placement of a pedicle screw.

In 2006, a study group was assembled to investigate the effectiveness of the PediGuard™ device for placement of the pedicle screw pilot drill hole, reducing pedicle screw breaches during thoracic and lumbar pedicle screw fixation of the spine. The first hypothesis is that the PediGuard™ would be more accurate for pedicle screw placement as compared to other standard manual techniques of pedicle screw insertion. The second hypothesis is that the PediGuard™ will not be inferior to fluoroscopic techniques for pedicle screw insertion; however, the radiation dose will be less in the PediGuard™ group.

### Materials and Methods

PediGuard™ is a wireless electronic handheld pedicle screw pilot hole preparation instrument designed to continuously monitor the electrical conductivity of the tissue at its tip throughout the drilling process. It provides audible and visual feedback in response to local tissue conductivity changes. This feedback allows the surgeon to discriminate between different types of tissue in contact with the tip, detecting possible vertebral cortex perforations. PediGuard™ has received FDA 510(k) clearance for commercial distribution in the US.

PediGuard™ features bipolar electrodes that avoid any shunting effect and keep the measured electrical conductivity independent of the insertion depth. When in the same medium, the electrical conductivity remains constant while the instrument is advanced into the vertebral pedicle. Variation occurs when the instrument passes through a boundary between two different media; for example, bone vs. blood. As shown in Figure 1, PediGuard™ consists of an awl instrument with a hollow handle that accepts a built-in electronic printed circuit board. The electronic components allow performing measurements, with translation to audible signal and colored LEDs (Light Emitting Diodes) to be used as feedback to the surgeon.

### Surgical Techniques Using PediGuard™

*Determination of the size and style of the probe.* First, the surgeon determines in which area of the spine the pedicles will be drilled. In the lower lumbar spine, generally a 4.0-mm diameter tip would be most advantageous. If one needs to go to L1 and L2 and, on radiograph, the pedicles look extremely small, one may wish to use 3.2 mm tip. If one is instrumenting most of the thoracic spine, the 3.2-mm or the 2.5-mm probe will be most advantageous.

There are two different styles of tip. The four-edge probe is much duller and is best used where there is soft cancellous bone within the pedicle. This would in most cases occur with degenerative spine in older patients. Where the cancellous bone is harder, it is recommended that one use the tri tip. Because the tri tip provides better control without having to push, it is widely preferred by surgeons.

*The PediGuard™ is used in an anticipatory function during drilling of the vertebral pedicle.* Due to the shape of the electromagnetic field at the tip of the device, the pitch and cadence of the sound emitted slightly changes before the nature of the bone or tissue changes.<sup>2</sup> When first entering the cancellous bone, keeping firm pressure is necessary to get a sense of the rate and pitch of the sound for that particular pedicle. As one advances, if the rate and pitch slow, then one is probably near or up against cortical bone. One can then gently reangle the tip, keeping firm pressure to look for the original sound of the cancellous bone. Once the sound of the original cancellous bone is heard, then one should advance the PediGuard™ in that direction. It is extremely important to not decrease pressure of the tip on the bone, or blood will intervene, and then a very high pitch and rate of sound will result. In addition, if one angles the tip too far in any one direction, then blood will seep in and surround the electrode tips, and a high pitched, high cadence sound will be heard as a consequence of the tip measuring blood.

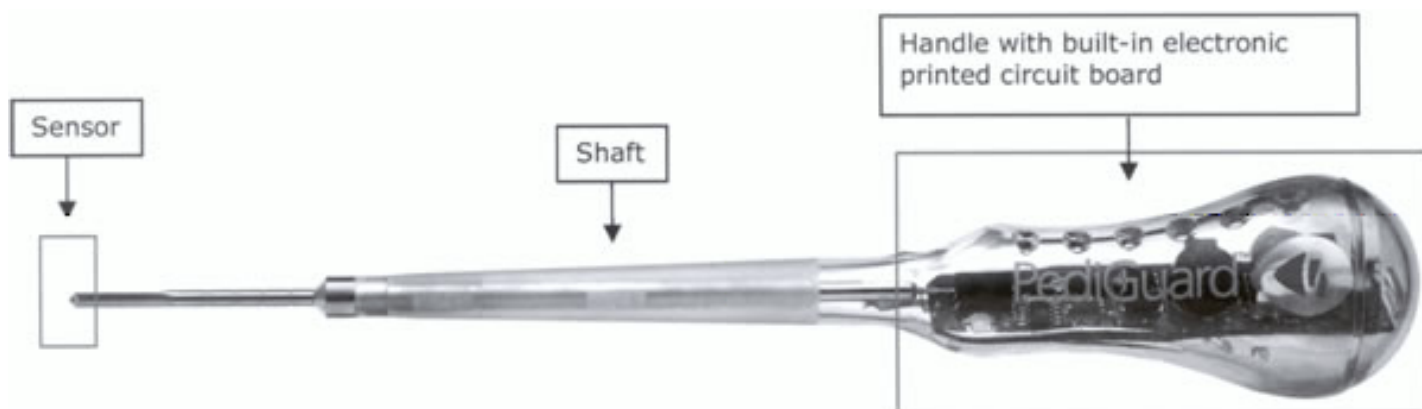


Figure 1. PediGuard™ Device

In difficult pedicle screw placements, this anticipatory function can also be used for placing a drill hole going from the outside in, especially in the thoracic spine. In this scenario, one may wish to slide down the lateral side of the transverse process and upper lateral wall of the pedicle. One can then assure that cortical bone has been reached by the slow rate and low pitched sound. Then, one can drill through the lateral cortex of the pedicle and enter the cancellous bone of the pedicle and then on to the vertebral body, assuring that the tip is contained within bone.

If one does perforate outside of the pedicle wall, either medially or laterally, the device will detect this with a high rate, high pitched sound. When this happens, the PediGuard™ device should be removed. One can still use bone wax or FloSeal or any other anticoagulant to try to decrease the bleeding out of the pedicle hole. One should then take a ball tip probe and palpate the walls of the pedicle to confirm the location of the breach. Sometimes, palpating the breach may be difficult, as the PediGuard™ is so accurate that only the very tip of the probe may perforate into the soft tissue before a large hole is made. Either way, if one can determine the location of the breach, one can redirect the PediGuard™ and create a new pedicle drill hole. One just reinserts the PediGuard™ device and puts it up firmly against cancellous bone and then begins drilling again. If the breach location is known (medial, lateral, superior, inferior), the surgeon can direct away from that. Otherwise, he or she should just continue to listen to the sound carefully and advance as appropriate. There are times when the surgeon cannot advance past the medial and lateral wall without perforation due to the starting hole entry point. It may be necessary on occasion to move the starting hole more laterally, even to the point of an outside-in technique, in order to pass through the pedicle morphology at that level.

### Study Design

The study design includes a randomized process of pedicle screw insertion in which the surgeon alternates between the pedicle drill hole being placed using PediGuard™ versus his or her other standard technique, either manual or fluoroscopic. The randomization occurs with the first hole drilled. Then, the insertion technique (PediGuard™ versus surgeon's standard technique) alternates with each additional screw going left to right and proximal. Once the pedicle drill hole is placed, all other aspects of the pedicle screw insertion, including tapping, screw insertion, and electrical stimulation, are the same for both techniques. As part of standard of care, a postoperative CT scan is performed on every patient. The CT scans were reviewed by a team of five surgeons very familiar with pedicle screw insertion, and consensus on the placement of each screw was required.

### Data Collection

Subjects who were scheduled to undergo thoracic and/or lumbar pedicle screw fixation during spine surgery were

recruited from the clinical practices of the six participating surgeons. Written IRB-approved informed consent was obtained during a pre-surgery office appointment and prior to randomization.

The technique for drilling the pedicle screw pilot hole developed by Dr. Harry Shufflebarger begins with obtaining a true AP image of the spine by rotating the fluoroscope and/or the patient. An awl is employed to initiate the starting hole. A 2.5 mm or 2.7 mm drill bit is utilized. The starting point is just lateral to the lateral wall of the pedicle, with drilling directed toward the medial pedicle wall. The angle of the drill varies with the vertebral rotation. The depth before passing medial to the medial wall of the pedicle is approximately 18–20 mm, assuring that one is past the spinal canal. The surgeon must determine the length of the flutes on the drill bit to enable determination of the depth of penetration of the drill. After the drill tip passes the medial pedicle cortex, it may be advanced a few mm further into the cancellous bone of the vertebral body. There is no set number of fluoro shots taken during this procedure; it is done according to the anatomy of each different level. For the side utilizing the PediGuard, a starting point image is obtained on the fluoroscope, and then the PediGuard is used to navigate the pedicle. Position and passage medial to the medial wall is still confirmed on the fluoroscope. In most circumstances, fewer fluoro shots are needed because the PediGuard provides its own feedback with regards to location within the pedicle. The pedicle screws are then inserted in a standard fashion. For this study, the number of fluoro shots were counted for each pedicle hole drilling, whether done with the standard method or with PediGuard.

## Results

### US Clinical Trial

Utilizing this consensus data, a group of 7 patients had titanium screws between T12 and S1 for degenerative surgical procedures, with 62 screws placed by a manual technique and 60 with the current PediGuard™. With the manual technique, 79% of screws were within 2 mm and 21% of pedicle screw breaches were out by greater than 2 mm. Using the PediGuard™, there was a trend toward significant improvement, with 86.7% being within 2 mm and 13.3% being out greater than 2 mm. This 8% improvement with PediGuard™ appears to be a significant clinical trend (Table 1).

**Table 1. Breaches T12 to S1, Titanium Screws, Degenerative Cases**

	PediGuard™ N = 60	Manual N = 62
Anterior	3 (5%)	4 (6.5%)
Lateral	3 (5%)	3 (5%)
Medial	1 (1.5%)	6 (9.5%)
Superior	1 (1.5%)	0
Total	8 (13%)	13 (21%)

An analysis of the direction of the breach shows a very significant reduction in medial breaches (Table 1). With the standard manual technique, 6 of 62 screws (9.5%) were out medially versus only 1 of 60 screws (1.5%) with the PediGuard™. Lateral and anterior breaches were similar. This finding of a six-fold reduction in medial breaches becomes more significant when considering that all screws were tested with EMG monitoring and recorded above 10 mA.

A study by Ul Haque, Shufflebarger et al.<sup>21</sup> on radiation exposure with all screw constructs in adolescent idiopathic scoliosis showed that a nonclassified radiation worker (i.e. the surgeon) inserting approximately 2,800 screws under fluoroscopic guidance received in one year the ten-year equivalent of allowable radiation for a nonclassified worker.

In the US clinical trial of PediGuard™, we analyzed deformity cases with titanium screws between T11 and S1 and compared screws inserted following drilling with fluoroscopic drilling alone versus PediGuard™. CT assessment of screws demonstrated breaches greater than 2 mm to be equal in both groups (Table 2). These data are encouraging because the perforation rate greater than 2 mm is equal by both techniques, the average time per screw is reduced by approximately 10%, and the average radiation exposure is reduced by approximately 30% with PediGuard™ (Table 3).

**Table 2. Percentage of Breaches: Deformity Cases T11-S1, Titanium**

	In	Out > 2 mm
PediGuard™	81.4	18.5
Fluoroscopy	80.7	19.2

**Table 3. Radiation Exposure**

	Time (seconds)	Number of Fluoro Shots
PediGuard™	211	3.2
Fluoroscopy	229	4.5

### Discussion

Other clinical studies have demonstrated the safety and efficacy of the PediGuard™ device. Bolger et al.<sup>3</sup> reported a clinical study of 28 patients with 147 screws to determine cortical perforations. A total of 23 (16%) vertebral cortex perforations out of the 147 manual pedicle drillings were confirmed. Of these 23 perforations, 22 (95.7%) were detected by the PediGuard™ during the procedure. A total of 12 vertebral cortex perforations (52.2%) were detected by the PediGuard™ but not by the physician.

During the second phase of this study, Bolger et al.<sup>3</sup> reported on an additional 374 pedicle drillings performed on 69 patients. Postoperative CT imaging showed 41 confirmed breaches (41 of 374, or 11%). The PediGuard™ had correctly detected 100% of the breaches. Pearson's correlation coefficient was 374.000 ( $P < 0.001$ ). Three false positives occurred where there was an increase in the frequency of the

beats; however, no break was detected in the pedicle cortex on postoperative CT scan. This so-called false positive can occur, as only the tip of the PediGuard™ goes through the cortex and a true hole is not made. The PediGuard™ drill hole can be redirected such that the final position of the screw on CT scan is then in a correct position.

### Conclusion

Preliminary analysis of patients having had surgery for degenerative conditions with titanium screws between T12 and S1 shows a significant clinical trend in reduction of breach (by 8%) using the PediGuard™ device and a six-fold reduction in medial breaches. In patients with deformity having titanium screws, performance between PediGuard™ and a fluoroscopic technique for creating a drill hole for pedicle screw insertion appears to be equal. However, data suggest that the average time per screw is reduced by approximately 10% and also the number of fluoro shots per screw are significantly reduced with the PediGuard™, reducing the average radiation exposure by approximately 30%.

### References

1. Belmont Jr PJ, Klemme WR, Robinson M, Polly Jr DW. Accuracy of thoracic pedicle screws in patients with and without coronal plane spinal deformities. *Spine*. 2002; 27:1558-66.
2. Bolger C, Bourlion M. Pedicle navigation in spondylolisthesis, ch. 28. In: Gunsburg R, Szpalski M. *Spondylolysis, Spondylolisthesis, and Degenerative Spondylolisthesis*. Philadelphia: Lippincott Williams & Wilkins; 2005.
3. Bolger C, Brayda-Bruno M, Kaelin A, Lazenec JY, Le Huec JC, Logroschino C, Saillant G, Zeller R. Electrical conductivity measurement: a new technique to detect iatrogenic initial pedicle perforation. *Eur Spine J*, in press.
4. Burton DC, Asher MA, Lai SM. Scoliosis correction maintenance in skeletally immature patients with idiopathic scoliosis. Is anterior fusion really necessary? *Spine*. 2000; 25:61-8.
5. Clements DH, Morledge DE, Martin WH, Betz RR. Evoked and spontaneous electromyography to evaluate lumbosacral pedicle screw placement. *Spine*. 1996; 21:600-4.
6. Donovan DJ, Polly Jr DW, Ondra SL. The removal of a transdural pedicle screw placed for thoracolumbar spine fracture. *Spine*. 1996; 21:2495-8.
7. Hackenberg L, Link TM, Liljenqvist U. Axial and tangential fixation strength of pedicle screws versus hooks in the thoracic spine in relation to bone mineral density. *Spine*. 2002; 27:937-42.
8. Jendrisak MD. Spontaneous abdominal aortic rupture from erosion by a lumbar spine fixation device: a case report. *Surgery*. 1986; 99:631-3.
9. Kim YG, Lenke LG, Bridwell KH, Kim KL, Steger-May K. Pulmonary function in adolescent idiopathic scoliosis relative to the surgical procedure. *J Bone Joint Surg Am*. 2005; 87:1534-41.
10. Kim YJ, Lenke LG, Bridwell KH. Comparative analysis of pedicle screw versus hook instrumentation in posterior spinal fusion of adolescent idiopathic scoliosis: a matched cohort analysis. Scoliosis Research Society annual meeting, Quebec City, Canada, September 10-13, 2003.
11. Kuklo TR, Lenke LG, O'Brien MF, Lehman Jr RA, Polly Jr DW, Schroeder TM. Accuracy and efficacy of thoracic pedicle screws in curves more than 90 degrees. *Spine*. 2005; 30:222-6.
12. Laine T, Makitalo K, Schlenzka D, Tallroth K, Poussa M, Alho A. Accuracy of pedicle screw insertion: a prospective CT study in 30 low back patients. *Eur Spine J*. 1997; 6:402-5.
13. Learch TJ, Massie JB, Pathria MN, Ahlgren BA, Garfin SR. Assessment of pedicle screw placement utilizing conventional radiography and computed tomography: a proposed systematic approach to improve accuracy of interpretation. *Spine*. 2004; 29:767-73.

14. Lenke LG, Rinella A, Kim Y. Freehand thoracic pedicle screw placement. *Semin Spine Surg.* 2002; 14:48-57.
15. Liljenqvist U. Comparative analysis of pedicle screw and hook instrumentation in posterior correction and fusion of idiopathic thoracic scoliosis. *Eur Spine J.* 2002; 11:336-43.
16. Papin P, Arlet V, Marchesi D, Rosenblatt B, Aebi M. Unusual presentation of spinal cord compression related to misplaced pedicle screws in thoracic scoliosis. *Eur Spine J.* 1999; 8:156-9.
17. Perisinakis K, Theocharopoulos N, Damilakis J, Katonis P, Papadokostakis G, Hadjipavlou A, Gourtsoyiannis N. Estimation of patient dose and associated radiogenic risks from fluoroscopically guided pedicle screw insertion. *Spine.* 2004; 29:1555-60.
18. Suk S-I, Choon KL, Won-Joong K, Yong-Jin C, Yong-Bum P. Segmental pedicle screw fixation in the treatment of thoracic idiopathic scoliosis. *Spine.* 1995; 20:1399-405.
19. Suk S-I, Kim W-J, Lee S-M, Kim J-H, Chung E-R. Thoracic pedicle screw fixation in spinal deformities: are they really safe? *Spine.* 2001; 26:2049-57.
20. Suk S-I, Lee CK, Min HJ, Cho KH, Oh JH. Comparison of Cotrel-Dubousset pedicle screws and hooks in the treatment of idiopathic scoliosis. *Internat Orthop (SICOT).* 1994; 18:341-6.
21. Ul Haque M, Shufflebarger HL, O'Brien MF, Macagno A. Radiation exposure during pedicle screw placement in adolescent idiopathic scoliosis: is fluoroscopy safe? *Spine.* 2006; 31:2516-20.
22. Yahiro MA. Comprehensive literature review. Pedicle screw fixation devices. *Spine.* 1994; 19:S2274-S8.
23. Yalcin S, Guven O. Reversible anterior cord syndrome due to penetration of the spinal canal by pedicular screws. *Paraplegia.* 1995; 33:423-5.