

BUSINESS BRIEFING

Global Surgery – Future Directions 2005

The Innovative New Hand-held Pedicle Drilling Tool
– A New Help for Pedicle Screw Insertion

a report by

André J Kaelin

*Chief, Department of Paediatric Orthopaedics, Children's Hospital, Head of Spinal Surgery,
Department of Orthopaedics and Traumatology, University Hospital of Geneva, and
Professor of Paediatric Orthopaedics, Medical School, University of Geneva*

The Innovative New Hand-held Pedicle Drilling Tool — A New Help for Pedicle Screw Insertion

a report by
André J Kaelin

Chief, Department of Paediatric Orthopaedics, Children's Hospital, Head of Spinal Surgery,
Department of Orthopaedics and Traumatology, University Hospital of Geneva, and
Professor of Paediatric Orthopaedics, Medical School, University of Geneva



Professor André J Kaelin is Chief of the Department of Paediatric Orthopaedics at the Children's Hospital, University Hospital of Geneva, and Head of Spinal Surgery at the Department of Orthopaedics and Traumatology, University Hospital of Geneva.

He is also Professor of Paediatric Orthopaedics at the Medical School, University of Geneva. Professor Kaelin has been a Fellow of Paediatric Orthopaedics at the Children's Hospital, Harvard Medical School in Boston (1982 and 1986), a Fellow of Paediatric Orthopaedics at the Alfred I Dupond Hospital, a Fellow in the Department of Paediatric Orthopaedics at the Hôpital Trousseau in Paris (1983) and a Fellow of Orthopaedic and Paediatric Surgery Training in Geneva. Moreover, Professor Kaelin is a former President of the Swiss Orthopaedic Association, a member of the board of the Spinal Society of Spine and the Groupe International Cotrel Dubousset (GICD), a member of Le Groupe d'Etude des Scolioses (GES), the European Paediatric Orthopaedic Society (EPOS), Le Groupe d'Etude en Orthopédie Pédiatrique (GEOP), Arbeitsgemeinschaft für Osteosynthesefragen (AO), the International Society of Orthopaedic Surgery and Traumatology (SICOT), La Société Française de Chirurgie Orthopédique et Traumatologique (SOFOT), l'Association pour l'Etude des Prothèses et Orthèses (APO), the International Paediatric Orthopaedic Think Tank (IPOTT), the Society of Pediatric Oncology (SIOP) and La Société Royale Belge d'Orthopédie.

In 1970, Roy-Camille was the first to describe spinal fixations in the form of metallic plates screwed into the vertebrae pedicles and articular apophyses. Since then, pedicle screws have been widely used to fix the spine posteriorly. The development of rigid fixation between pedicle screws and longitudinal bars, anatomy knowledge and better imaging tools convinced surgeons to gradually switch from hooks to pedicle screws.

After long discussion, the US Food and Drug Administration (FDA) cleared pedicle screws as a class 2 device in 1995. Used first in the lumbar area, then in the cervical area, screws are currently also inserted in the thoracic spine. Despite numerous technical aids, the accurate insertion of screws remains a challenge. Therefore, training and learning form a vital part of the success of the technique. As the pedicle is the strongest part of the vertebrae, the transpedicular fixation is used widely in the following indications:

- correction of deformities (scoliosis, kyphosis);
- stabilisation of fractures;
- stabilisation and correction of spondylolisthesis;
- stabilisation and correction degenerative spinal lesion and narrow canal;
- stabilisation and correction after infection;
- reconstruction after tumour resection; and
- secondary spinal surgery.

In order to improve the placement of screws and achieve better control of complications, research and development activities are being focused on the following areas:

- morphological and anatomical description of pedicles;
- description of landmarks for entry point and orientation (see *Figure 1 A and B*);
- technique of performing pedicles perforation;
- perioperative static imaging (fluoroscopy for open surgery, computed tomography (CT) for percutaneous procedures) as a guidance;
- computer-assisted surgery guidance in realtime (CT- or fluoroscopy-based);
- somato- and/or motor-evoked potential peri-

- operative recording; and
- electromyographic (EMG) stimulation.

The rates of misplaced screws (10% to 40%) and complications (2% to 20%) vary depending on the authors (see *Figure 1 C and D*). Realtime computer-assisted surgery guidance decreases the risk of misplacement to less than 10%, but heavy equipment is expensive (US\$150,000–250,000) and is not available in all institutions. Misplacement means that screws are inserted completely or partially outside of the pedicle or protruding out of the bone – complications implicate neurological or vascular injuries followed by deficit or pain. Poor bone purchase and secondary mobilisation of the instrumentation are not usually reported in clinical literature. The true rate of permanent impairment and second-look surgery is still unknown.

The PediGuard™ System

This article presents the technical originality, the clinical use and the relevance of the PediGuard system. PediGuard is an innovative, new hand-held drilling tool from SpineVision®, which allows realtime navigation through the pedicle. PediGuard is a user-friendly tool that can detect cortex perforation in the pre-insertion screw hole preparation. It is used as a pedicle awl allowing the surgeon to use his/her usual aiming technique – free-hand or fluoroscopy – and choose, without any constraint, the entry point and direction of the drill hole.

The PediGuard system consists of an awl instrument with a hollow handle that holds a battery-powered electronic cartridge. The awl is provided either as a single-use device that is completely sterile and intended to be used and discarded immediately or as a reusable handle with a single-use disposable battery pack. Several sizes of the awl are provided for use. The tip of the awl is currently offered in two different sizes – 3.2mm or 4mm. The choice of size depends on the desired size of hole that the surgeon wants to drill in the pedicle. If the surgeon requires a 3.2mm hole, he/she will choose the PediGuard instrument with the smaller sized tip.

The awl is used specifically in drilling pilot holes for screws placed in the vertebrae during spinal surgery. The shaft of the awl is made of stainless steel and the hollow handle is plastic. The 15cm-long shaft consists of an 11cm-long cylindrical part with a diameter of 8mm and a 4cm-long drill with a diameter of 4mm – the 3.2mm drill has a 3.5cm tip. The conical part that joins the two parts of the shaft prevents the perforation from being too deep. The shaft has an external cylindrical mantle and an isolated core that appears at the tip. The electronic part induces electric impulses and the electrical conductivity is measured at the tip. Inside the handle of the awl is an electronic cartridge with a printed circuit board and electronic components. The cartridge contains a beeper and yellow and green light-emitting diodes (LEDs), which are used as alarms triggered by the variation of the electrical conductivity at the tip of the shaft.

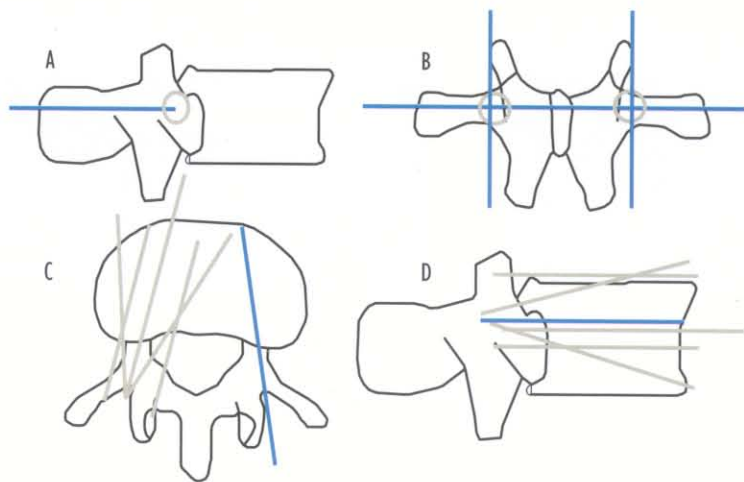
Experimental Animal Study

The first PediGuard study was conducted in 2002. A total of eight pigs, ranging in weight from 60kg to 90kg, were used in the study following identical study methods for each animal. The animals were anaesthetised and the thoracic and lumbar spinal areas were exposed. A total of 14 pilot holes were drilled into the pedicles of the spine in each animal using PediGuard. When the 'beep' sound of the device increased in pitch and in cadence – indicating that the electrical conductivity had increased significantly at the distal tip of the shaft – the tip was considered to be touching soft tissue rather than bone and the device was deemed to have detected a perforation. A radiopaque marker was then placed at the point of perforation.

If no perforation was detected while drilling the hole, a 4mm marker rod was inserted to its maximum depth. The animals were sacrificed and the vertebral levels were removed. The spines were then dissected and evaluated to compare actual vertebral perforation to PediGuard 'detections' made during the surgery.

A total of 112 screw holes were made in the spines of the pigs, which resulted in a total of 51 perforations of bone (45.5%). PediGuard detected 49 of the 51 perforations (96%). Among those 49 perforations, PediGuard was sensitive enough to detect 10 cases of cartilage growth. In only two cases did the system fail to detect a perforation of bone when the tip of the device was actually in contact with soft tissues. In both cases, the false-negative resulted in a minor cranial effraction in the intervertebral disc. There were no false-positives, i.e. the system did not indicate soft tissue contact when post-operative evaluation revealed that there was none.

Figure 1: Screw Insertion



A, B: Anatomical landmarks for screw insertion in lumbar area – lateral and posterior view.
C, D: The blue lines show the correct direction for screw insertion. The beige lines show all possible misplacements, transverse and sagittal view. Trajectories in conflict with the contents of the canal or the roots run a higher risk of neurological injuries. Anterior screws that are too long increase the risk of vascular lesions.

Moreover, the doctor only detected 34 of the 51 perforations manually (66.7%). In other words, PediGuard detected 15 perforations that the doctor failed to detect – excluding cartilage growth detection.

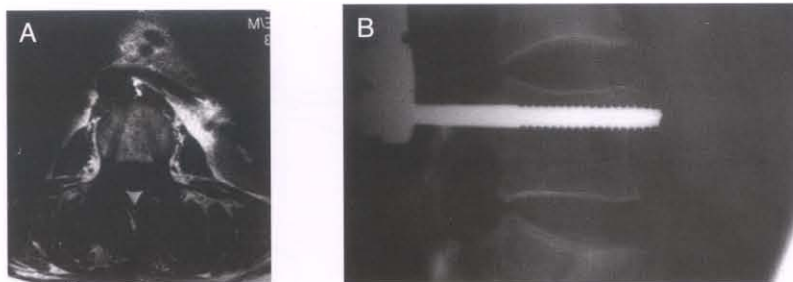
PediGuard demonstrated a 100% positive predictive value (PPV), a 97% negative predictive value (NPV), 100% specificity and 96% sensitivity. Thus, the device was shown to measure tissue electrical conductivity and produce reliable feedback to the surgeon when drilling pilot holes in spinal surgery.

Multicentric Clinical Study

Accidental perforation of the vertebral cortex is a surgical risk associated with the standard methods of pedicle screw insertion. Complications such as dysaesthesia or paraplegia may result from these misplaced implants. Current techniques do not guarantee correct pedicle screws placement. A preliminary clinical evaluation was conducted to assess the safety and efficacy of PediGuard.

Methods

A total of 147 manual pedicle drillings were performed in 11 European hospitals during 28 spinal surgeries, performed between September 2002 and March 2003. A comparison was made between the device indications and other detection possibilities – such as a surgeon's tactile feeling, mechanical probing, fluoroscopy, CT scans, EMG, SomEsthetic Evoked Potential (SEEP) and surgical navigation – depending on their availability, pre- and/or post-operatively. The detections of vertebral cortex fractures were therefore registered and compared as indicated by the device or by any other available possibility.

Figure 2: Pedicle Screw Placement

A: Magnetic resonance imaging (MRI) showing correct trajectory and good position and direction after implant removal.
 B: Perforation of the anterior cortex with the risk of aortic or venae cava lesion.

Figure 3: PediGuard with the LED Illuminated

Results

On 147 drillings, 23 vertebral cortex fractures (16%) were confirmed. Out of these 23 fractures, the device detected 22, leading the surgeons to stop drilling, check and reconsider initial trajectories when necessary. In one case, the neuro-stimulator integrated to the device induced visible leg twitches, simultaneously with an audio signal rise of the drilling instrument. There was one false-positive detection – i.e. the beeps rise, but no fracture confirmed. Employing this instrument did not add any noticeable time to the surgeries and it was considered easy to use. No adverse effect was observed.

Case Studies

In the author's department, the PediGuard system is used when more than four pedicle screws have to be implanted for a single case. In 48 particular patients, the indications were 19 spinal deformities, nine spondylolisthesis, eight fractures and 12 degenerative lesions, i.e. scoliosis and narrow canal. A total of 326 screws were inserted into these patients, with a mean screws insertion per patient of 6.8 (four to 12), from D8 to S1. The entry point was defined according to the anatomical landmark. The cortical bone was removed with a rongeur.

Using PediGuard

First, the PediGuard is set up by pushing the trigger at the top of the handle. The device must remain silent and the green light flash continuously. PediGuard is then tested by inserting the tip of the shaft into the

patient blood or in a bowl filled with saline solution. This should make the beeper sound with high frequency and tonality and the diode should flash more quickly. Subsequently, PediGuard can be used as a pedicle awl, with a beep of low frequency and tonality signalling perforation of cancellous bone or cortex and a loud, high-frequency beep signalling the approach of bone limits.

For fractures, degenerative lesions and screws in thoracic area for scoliosis, PediGuard and the image intensifier are used horizontally to confirm that the direction is good. For highly displaced spondylolisthesis, PediGuard is used in conjunction with computer-assisted surgery with three-dimensional (3-D) realtime guidance. For adolescent idiopathic scoliosis in lumbar and low thoracic area, fluoroscopic imaging is difficult due to the 3-D deformity, which is why the pedicles will then only be drilled with the aid of PediGuard and the surgeon's 'feeling'. The risk of neurological lesion in lumbar and low thoracic area is low because the pedicles are very thick and resistant in young patients. The risk of root compression is smaller than in degenerative cases because the space for neural structures is not limited by protruding disks or osteophytes. The author's department prefers the 3.2mm instrument, which has a sharper cut.

Results

For 326 cases of drilling, perforation of bone cortex occurred in 78 cases (24%); in 37 cases (11.3%) the surgeon also detected the perforation and in 41 cases (12.6%) the perforation was only detected by PediGuard. In two cases (0.6%), false-positive signals were noticed, but there were no false-negatives. After surgery, no neurological deficit or impairment due to screws misplacement was recorded. On X-rays, one of the screws perforated the superior vertebral plateau, its tip being in the anterior part of the annulus. For these 48 patients, no screws needed to be retrieved and no second look was performed.

Conclusion

After proper training, PediGuard is an instrument that is reliable and easy to use and its cost – compared with other instrumentation – is very affordable. No hardware or ancillary tools are necessary, the surgeon can use his/her usual techniques and it is not time-consuming. Animal tests and actual spinal surgeries did not reveal any complications or adverse effects. ■

A version of this article containing references and additional graphics can be found in the Reference Section on the website supporting this business briefing (www.touchbriefings.com).